

# Diffuse large B-cell lymphoma: review and refresh

Fiona E. Craig, MD

Mayo Clinic, Phoenix, Arizona

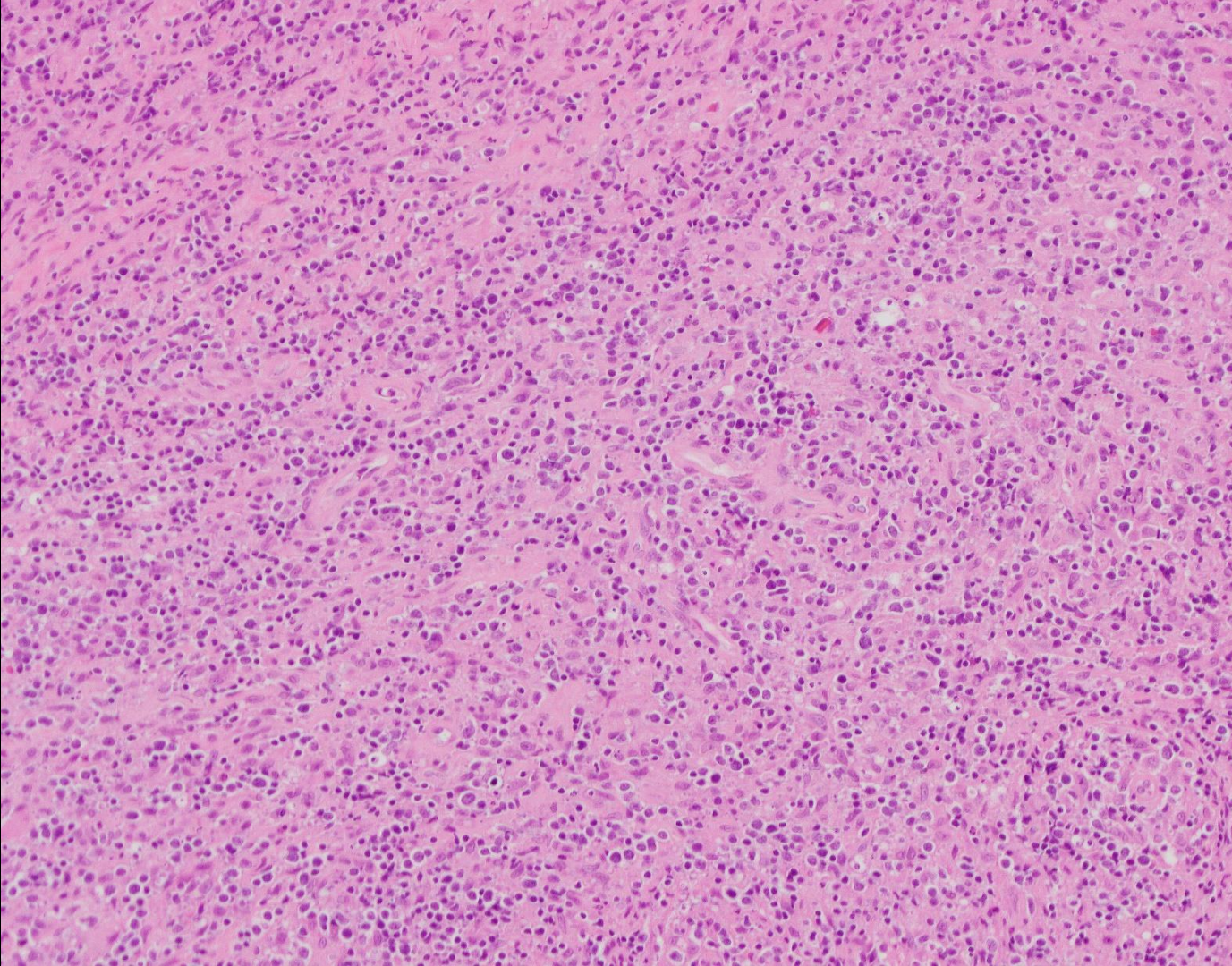
# Disclosures

I do not have financial/other relationships with the manufacturer(s) of commercial product(s) or provider(s) of commercial service(s) that would affect my views discussed in this educational activity.

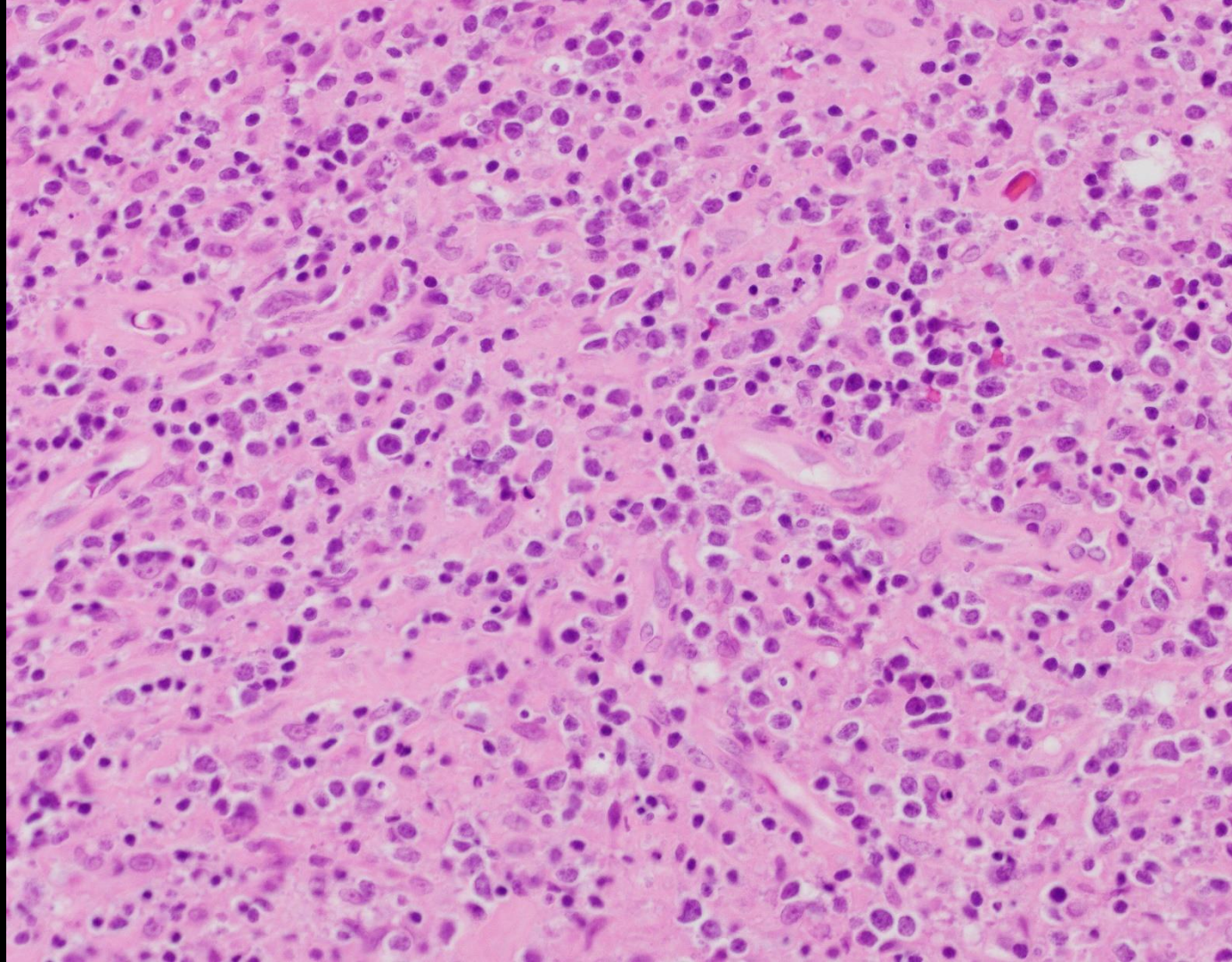
# Diffuse large B-cell lymphoma (DLBCL): review and refresh

1. Describe features characteristic of DLBCL, NOS, and outline an approach to diagnosis that includes consideration of small biopsy specimens.
2. Discuss the distinction between DLBCL, NOS and other subtypes of large B-cell lymphoma including EBV-positive DLBCL, primary DLBCL of the CNS, primary mediastinal large B-cell lymphoma, and ALK-positive large B-cell lymphoma.
3. Discuss the distinction between DLBCL and high-grade B-cell lymphoma, including Burkitt lymphoma, Burkitt-like lymphoma with 11q aberration, and HG B-cell lymphoma with MYC and BCL2 and/or BCL6 rearranged.

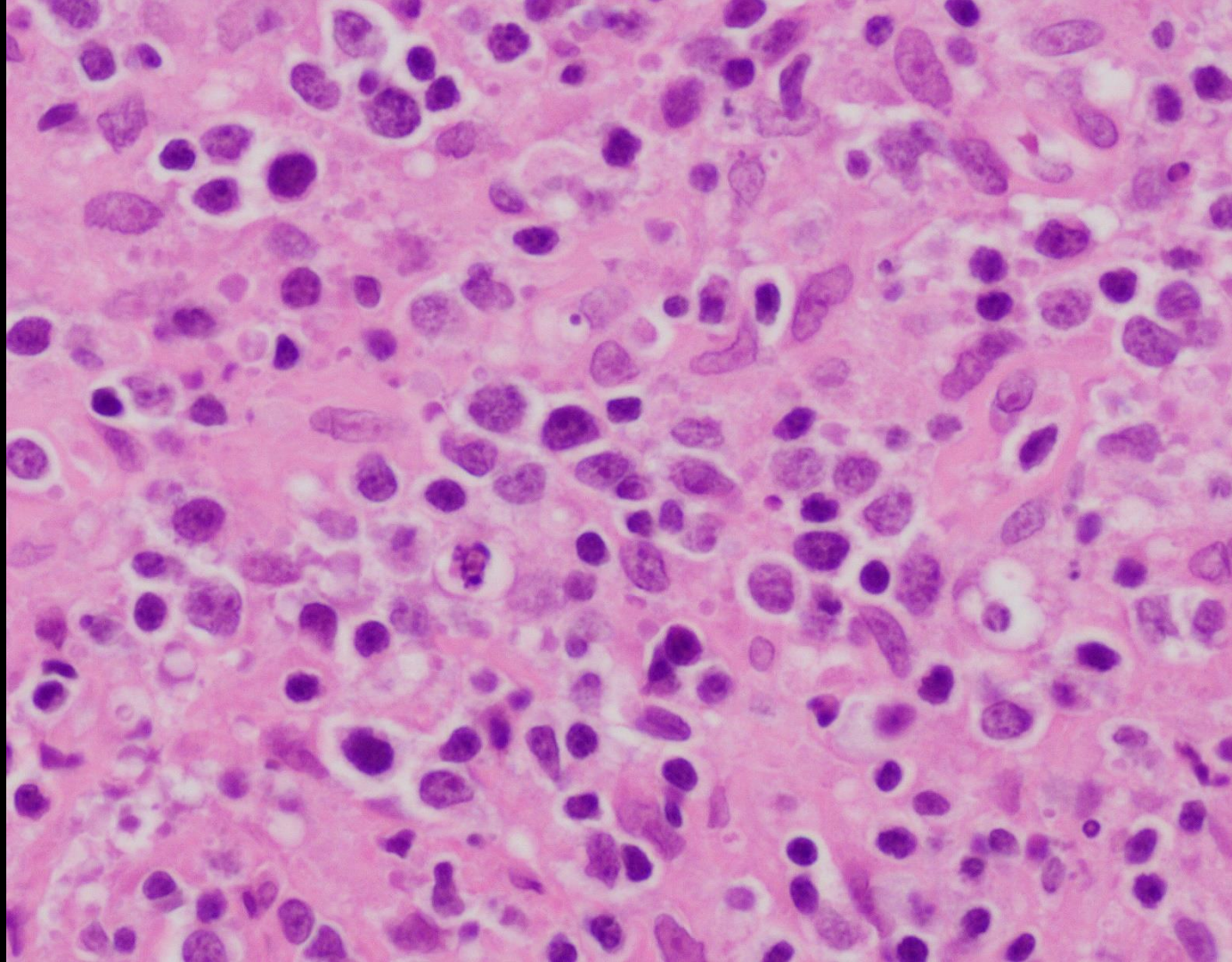
Case 1

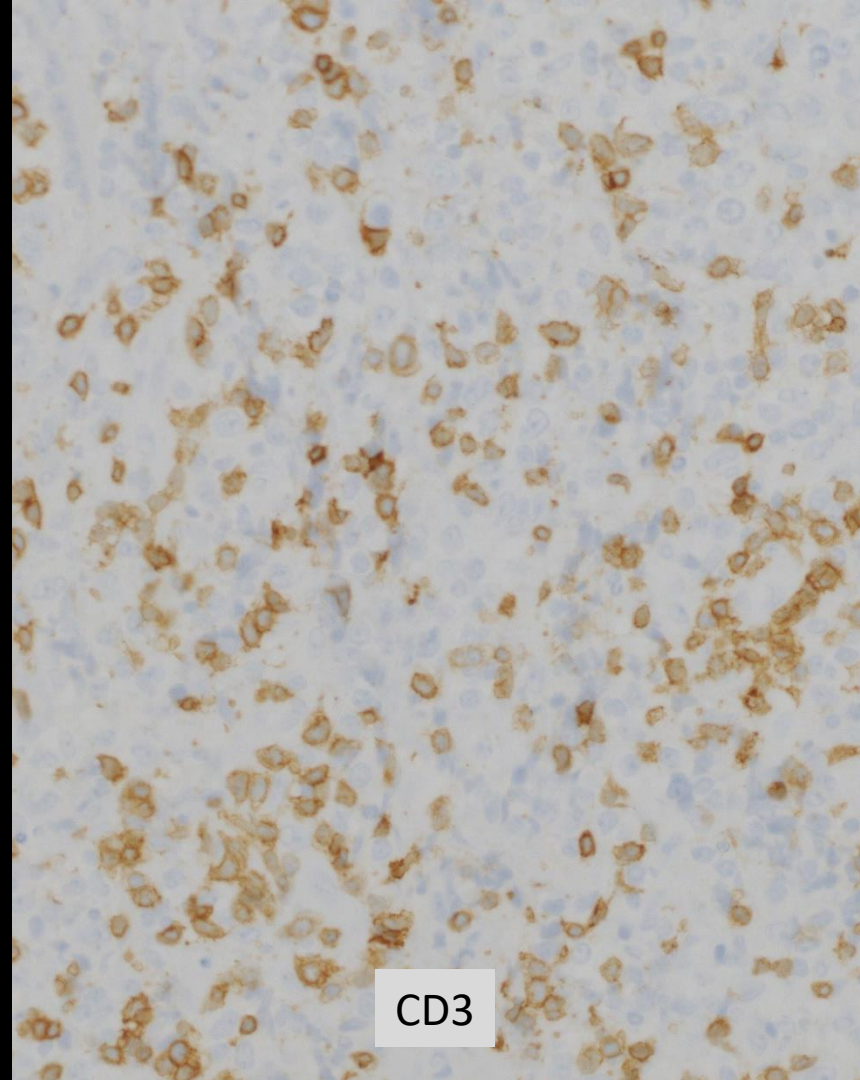
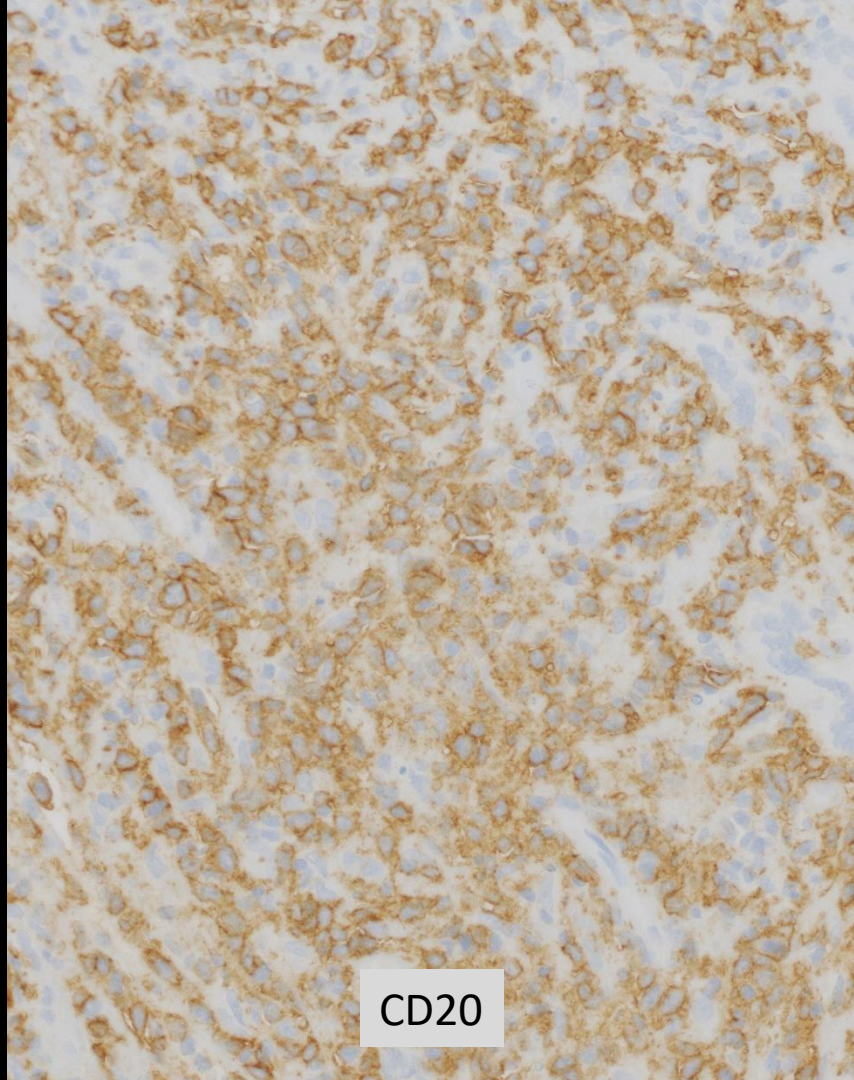


# Case 1



# Case 1






Identify a B-cell lymphoma, with morphologic features of diffuse large B-cell lymphoma (DLBCL), High-grade B-cell lymphoma (HGBCL) or Burkitt lymphoma



Conserve tissue (consider separating cores into more than one block, cutting unstained slides for possible future testing, and not facing block when obtaining additional sections).



Exclude other categories of B-cell lymphoma or leukemia :

- B-lymphoblastic leukemia / lymphoma e.g. blastic morphology, CD34+, TdT+
- Mantle cell lymphoma (blastoid and pleomorphic variants) e.g. morphologic features, Cyclin-D1, SOX11
- Follicular lymphoma e.g. CD21 or CD23 to highlight FDC meshwork structures



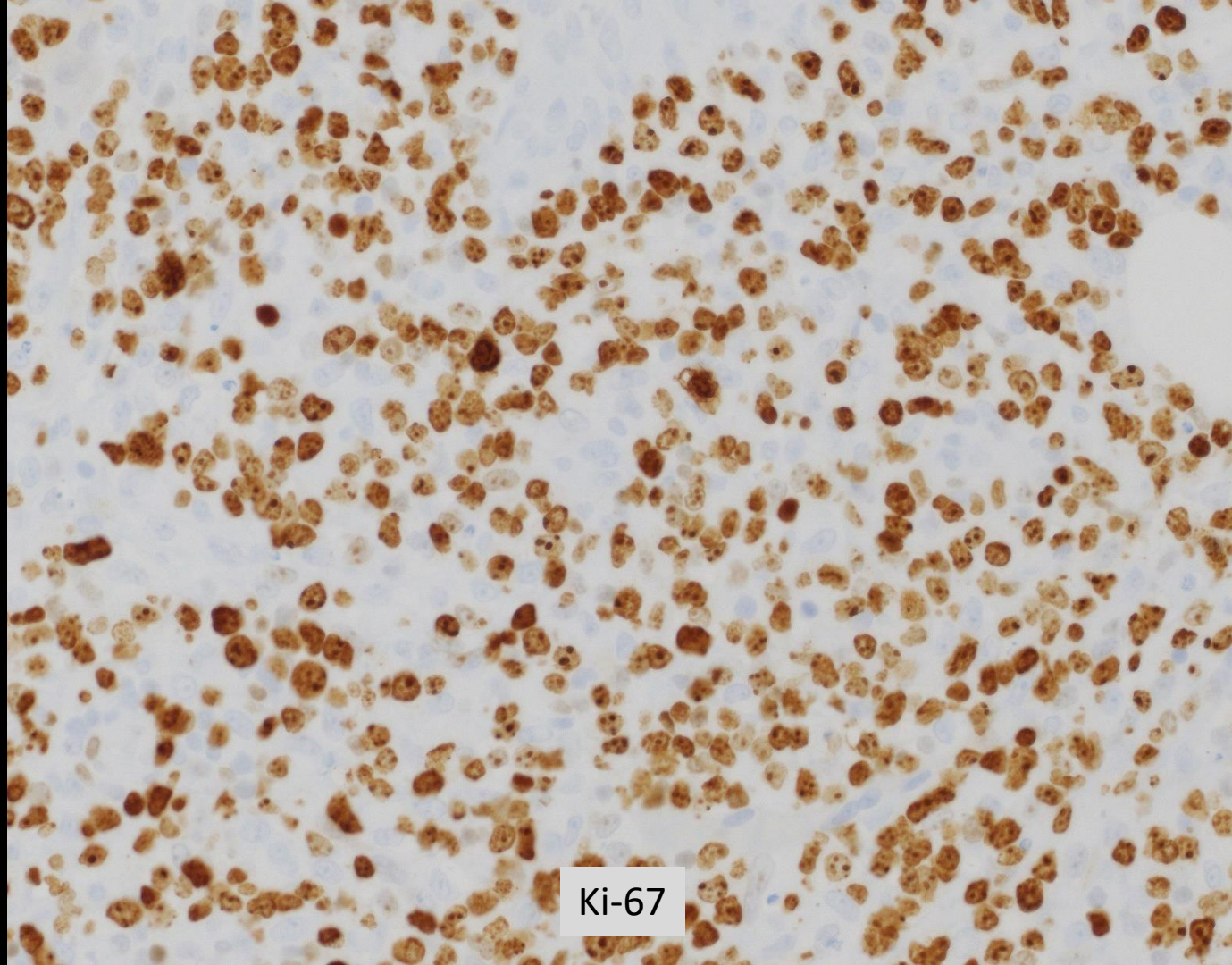
# Mantle cell lymphoma

- Usually (not always) CD5+, CCND1+, SOX11+
- >95% MCL translocation CCND1, most commonly IGH-CCND1
- Pleomorphic mantle cell lymphoma (PMCL) is composed of large cells with pleomorphic nuclei, relatively finely chromatin and nucleoli (DLBCL mimic)

# Lymphoblastic lymphoma

- Usually fine chromatin (blastic like “acute leukemia”)
- CD34+, TdT+, CD10br+, myeloid antigen +/-, CD45dim+, slg-, CD20 dim+/-
- DLBCL and HGBCL may be CD45dim+, slg-, and have dim/variable CD20.
- HGBCL may have partial TdT.

# Case 1



Ki-67

SIg(-)  
CD10(-)  
TdT(-)  
CD34(-)  
Cyclin-D1 (-)

If preliminary diagnosis is required before FISH studies are completed, consider using one of the following two options based on the morphologic features:

Appearance  
compatible with  
DLBCL

Blastoid  
appearance

“B-cell lymphoma, diffuse large  
or high-grade; pending  
additional studies for further  
classification”

“B-cell lymphoma, high-grade;  
pending additional studies for  
further classification”

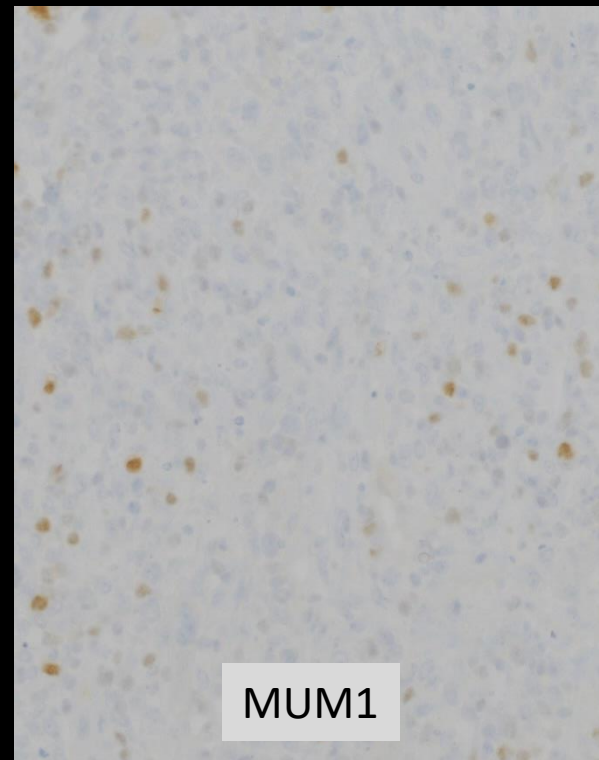
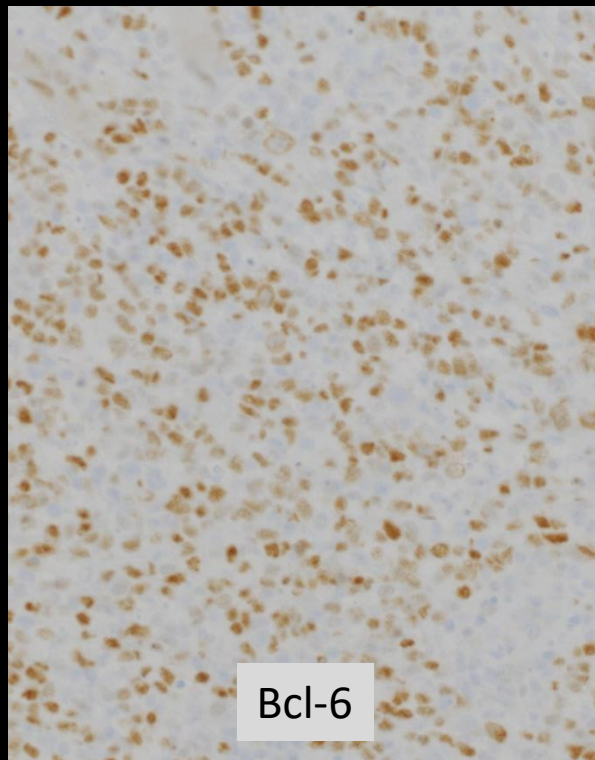
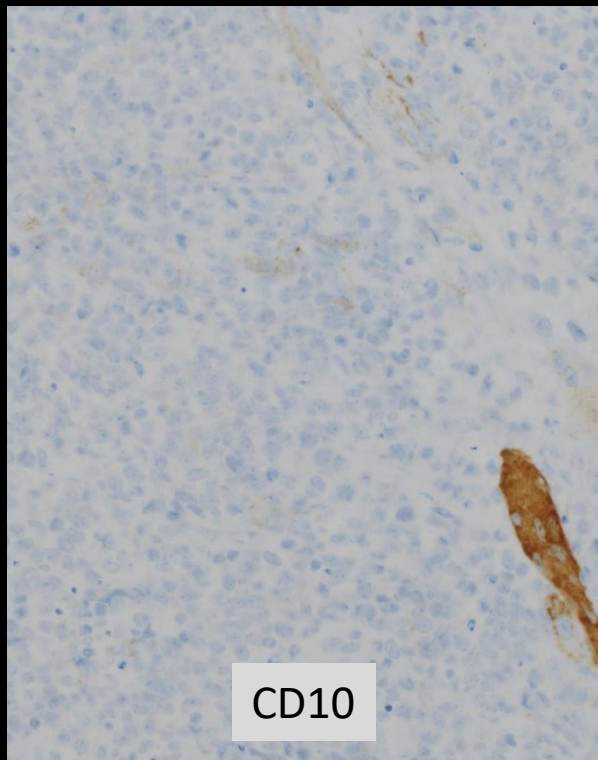
Submit for additional studies, as tissue permits, with the following priority:

1. Fluorescence in situ hybridization (FISH) studies for rearrangement of MYC and BCL2 and/or BCL6 genes (recommended using both MYC break-apart and MYC/IGH fusion probes).
2. Cell of Origin for DLBCL either by IHC using the Hans algorithm (CD10, BCL6, MUM1) or Lymph2Cx gene expression profiling.
3. BCL2 and MYC protein expression by IHC for DLBCL double expresser status.
4. Consider EBER in situ hybridization for Epstein-Barr virus (EBV), if clinically indicated.

# Case 1:

- Fluorescence in situ hybridization studies:
  - Negative for rearrangement MYC, BCL-2 or BCL-6, and no fusion of MYC and IgH
- Expression of Myc and Bcl-2 protein:
  - Negative
- Cell of origin (Hans):
  - Germinal center B-cell

# Case 1

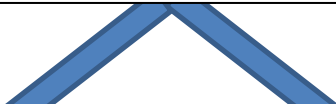

# DLBCL Cell Of Origin

- Germinal Center B (GCB) vs. Activated B-cell (ABC)
- Immunohistochemistry e.g. Hans algorithm surrogate
- Gene expression profiling:
  - Initially performed on fresh/frozen tissue
  - FFPE assay using Nanostring technology (Lymph2Cx)



“B-cell lymphoma, diffuse large or high-grade; pending additional studies for further classification”



Absence

*MYC* and *BCL2* and/or *BCL6* rearrangements by FISH, and other features



DLBCL; mention if double expresser *MYC* and *BCL2* proteins; cell of origin

Presence

*MYC* and *BCL2* and/or *BCL6* rearrangements by FISH, and other features

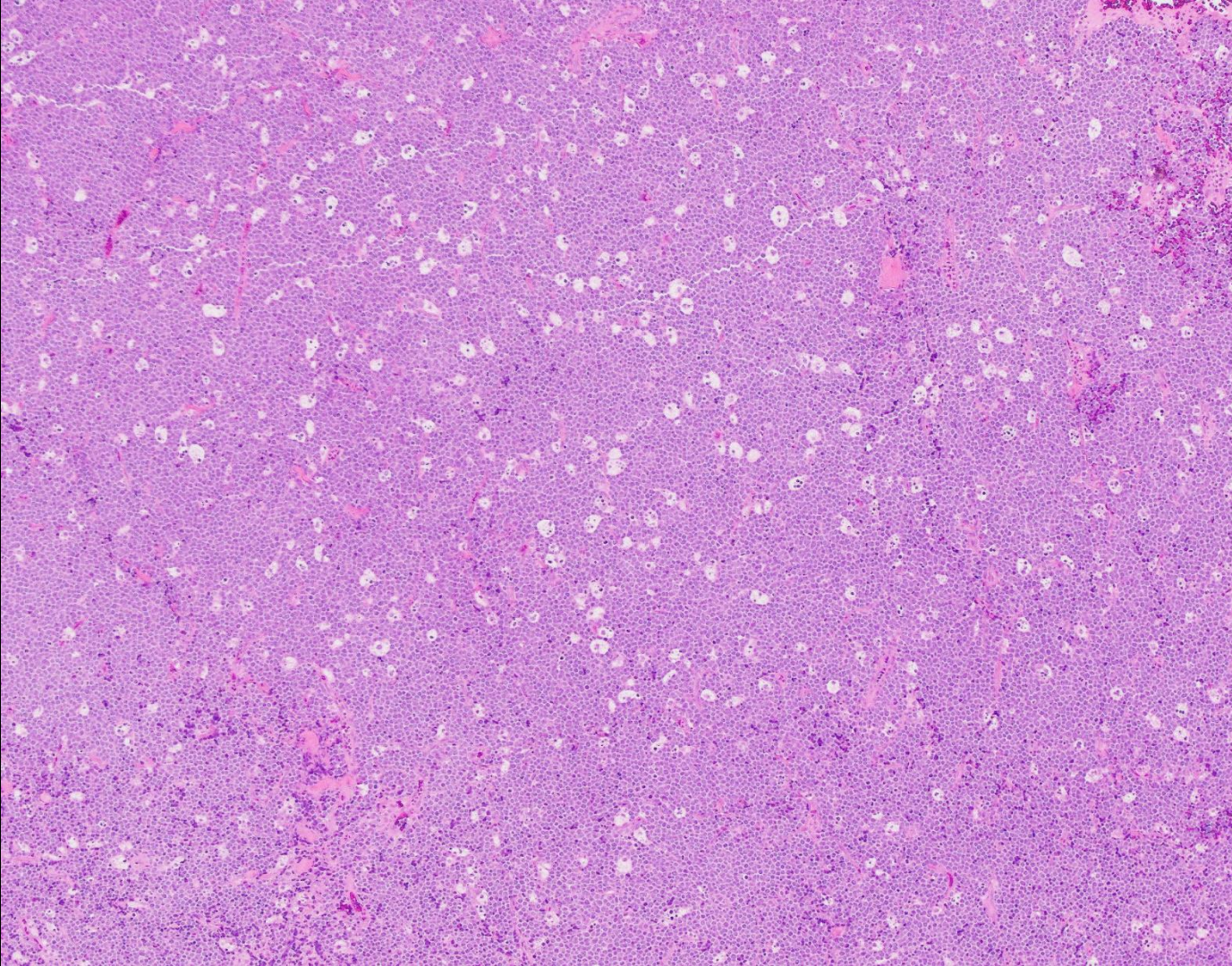


HGBCL with *MYC* and *BCL2* and/or *BCL6* rearrangements

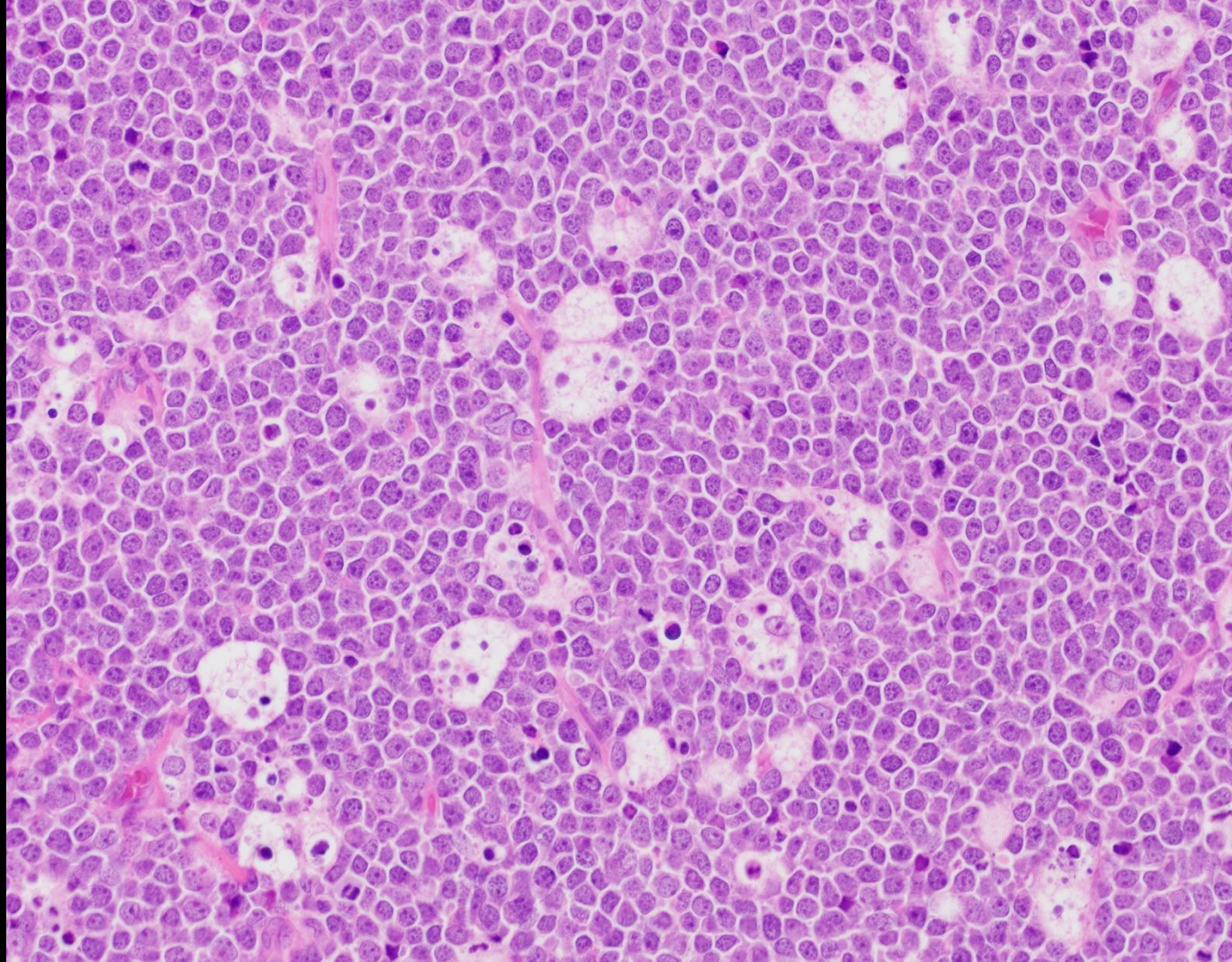
# EBV+ diffuse large B-cell lymphoma, NOS

- Consider immunosuppression e.g. congenital, HIV, iatrogenic (post-transplant, methotrexate, ...)
- Consider lymphomatoid granulomatosis
- De novo:
  - Most > age 50 years (immunosenesescence?)
  - Nodal or extranodal
  - Variably transformed and Reed-Sternberg-like cells
  - Often with admixed reactive cells (polymorphic)

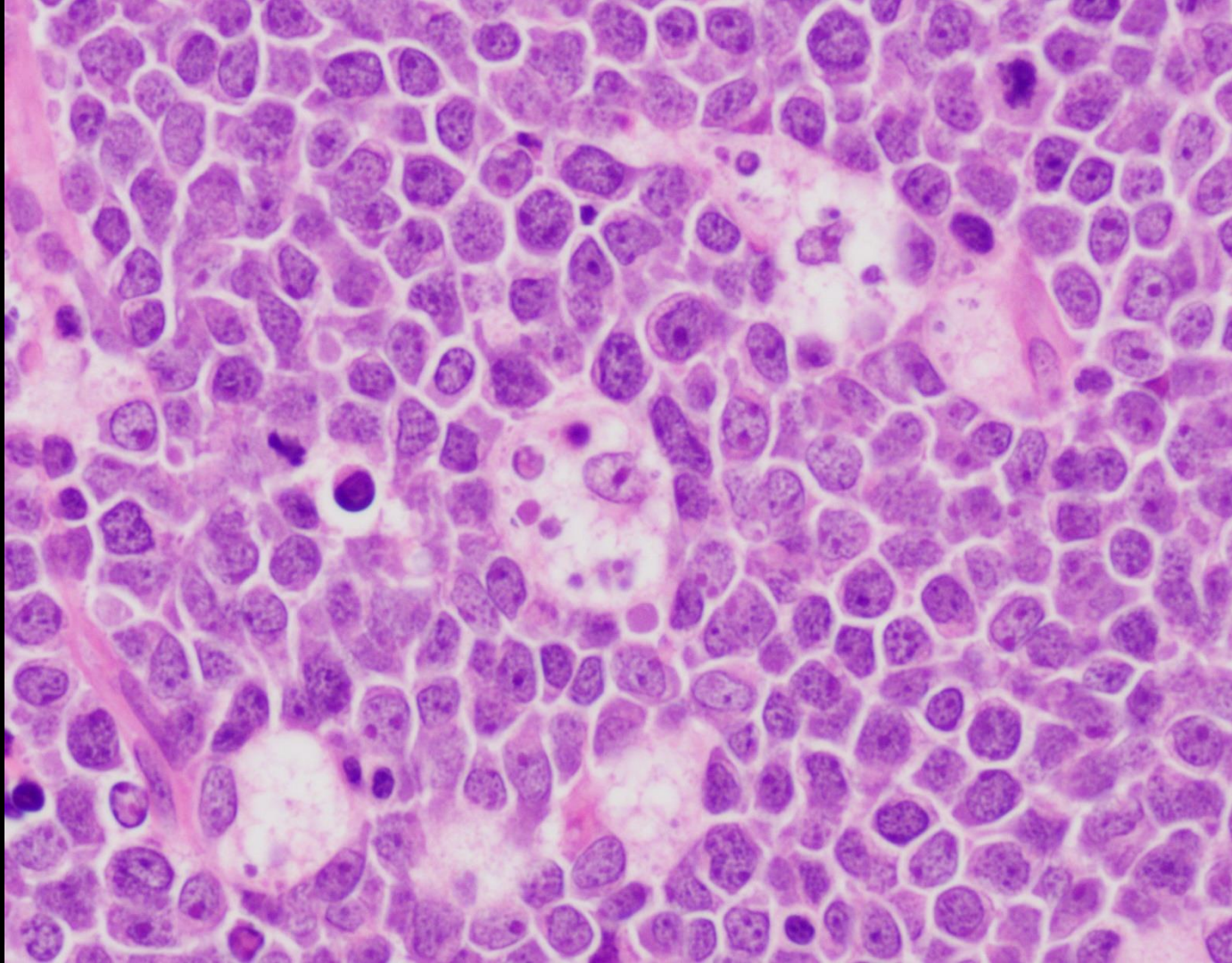
Case 2



Case 2



Case 2



If preliminary diagnosis is required before FISH studies are completed, consider using one of the following two options based on the morphologic features:

Appearance  
compatible with  
DLBCL

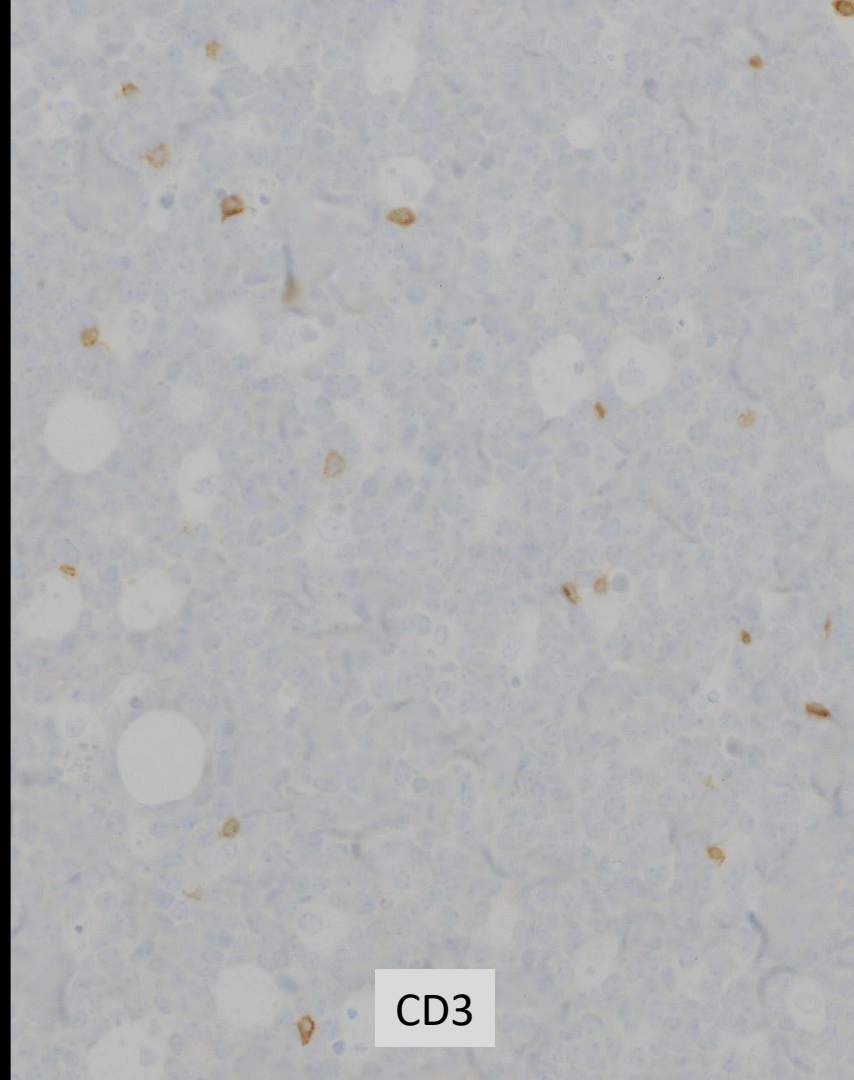
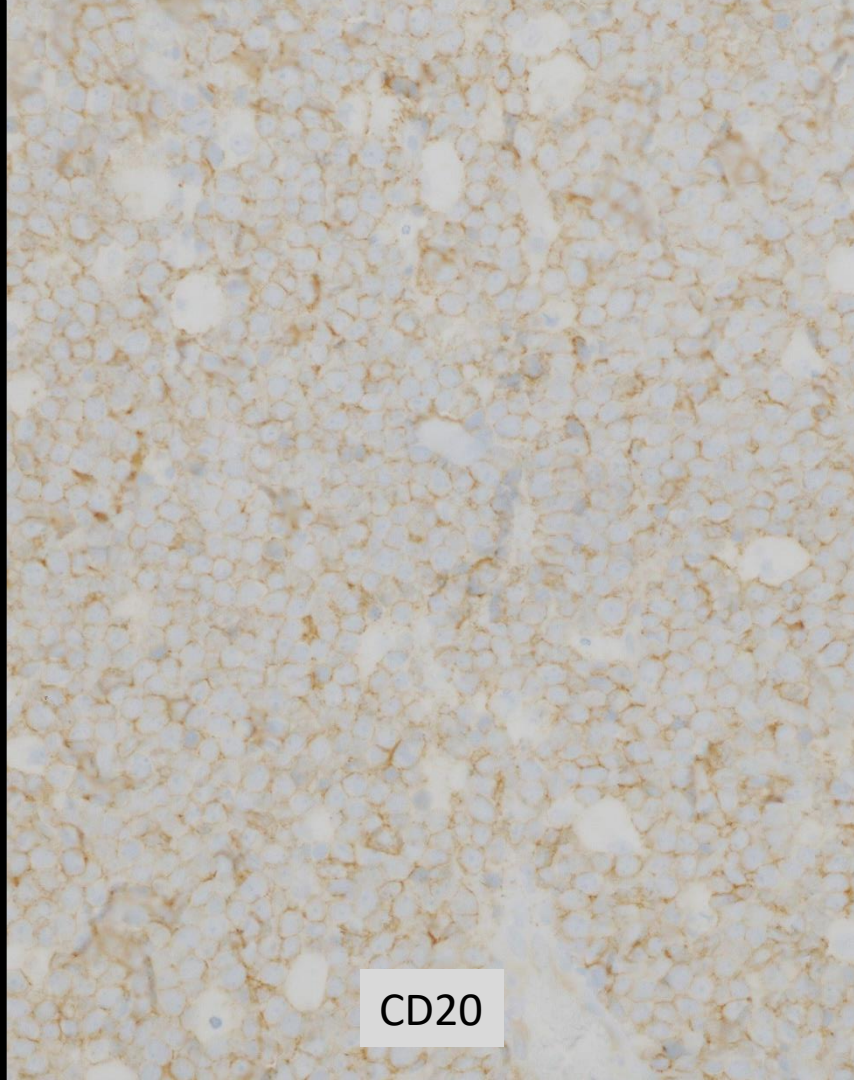
Blastoid  
appearance

“B-cell lymphoma, diffuse large  
or high-grade; pending  
additional studies for further  
classification”

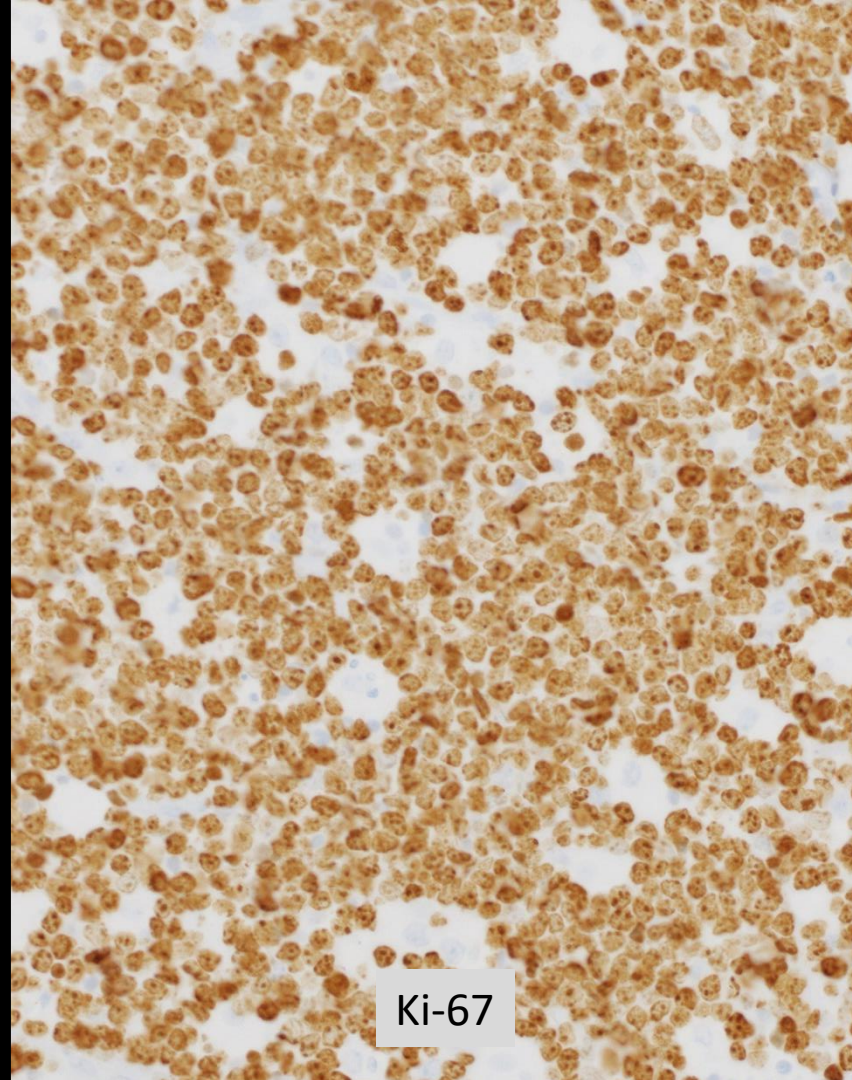
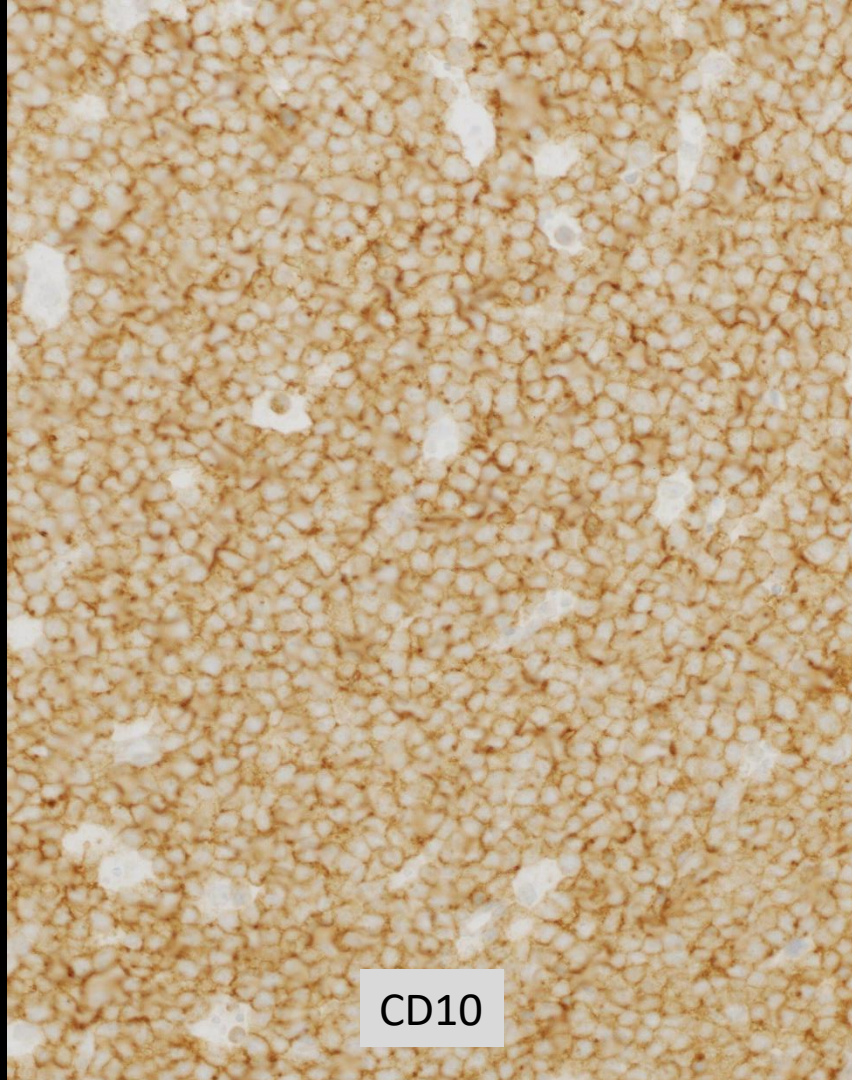
“B-cell lymphoma, high-grade;  
pending additional studies for  
further classification”

Submit for additional studies, as tissue permits, with the following priority:

1. Fluorescence in situ hybridization (FISH) studies for rearrangement of MYC and BCL2 and/or BCL6 genes (recommended using both MYC break-apart and MYC/IGH fusion probes).
2. Cell of Origin for DLBCL either by IHC using the Hans algorithm (CD10, BCL6, MUM1) or Lymph2Cx gene expression profiling.
3. BCL2 and MYC protein expression by IHC for DLBCL double expresser status.
4. Consider EBER in situ hybridization for Epstein-Barr virus (EBV), if clinically indicated.







## Case 2:

- Fluorescence in situ hybridization studies:
  - MYC/IGH fusion 97%; 8q24.1 (MYC sep) 92%
  - Negative BCL2 and BCL6 rearrangements
- Chromosome studies:
  - 46,XX,add(14)(q32)[18]/46,sl,i(7)(q10)[2]

“B-cell lymphoma, high-grade;  
pending additional studies for  
further classification”

Presence  
*MYC* and *BCL2* and/or  
*BCL6* rearrangements  
by FISH, and other  
features

Presence  
*MYC* gene  
rearrangem  
ent only,  
and other  
features

Absence  
*MYC* and *BCL2*  
and/or *BCL6*  
rearrangements  
by FISH, and  
other features

HGBCL with *MYC* and *BCL2*  
and/or *BCL6*  
rearrangements

Burkitt  
lymphoma

HGBCL, NOS

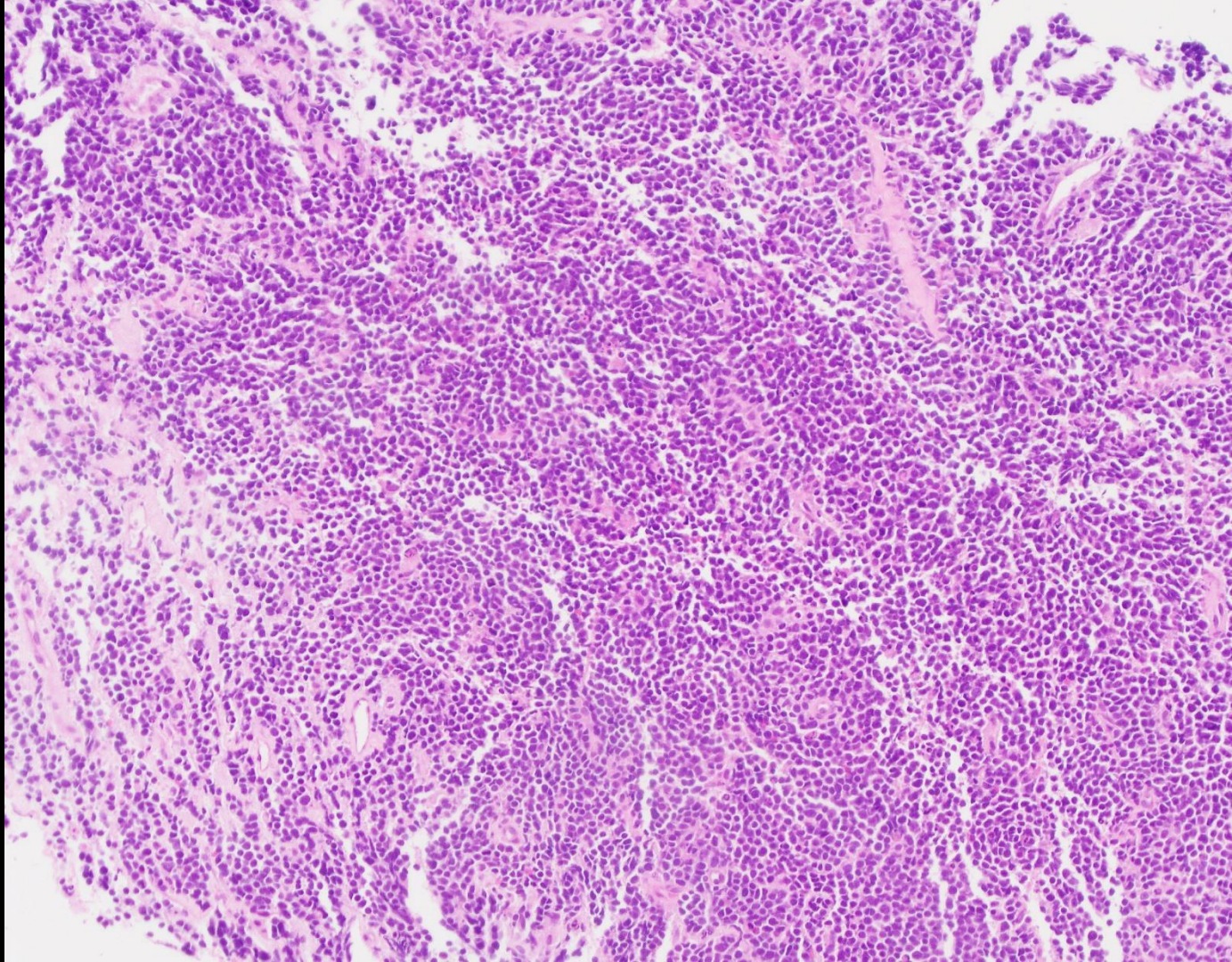
# Burkitt lymphoma

- Usually isolated MYC gene rearrangement
- Additional chromosome abnormalities may occur, including gains of 1q, 7 and 19p, but usually not complex karyotype
- Approximately 10% classic Burkitt lymphoma lack identifiable MYC rearrangement

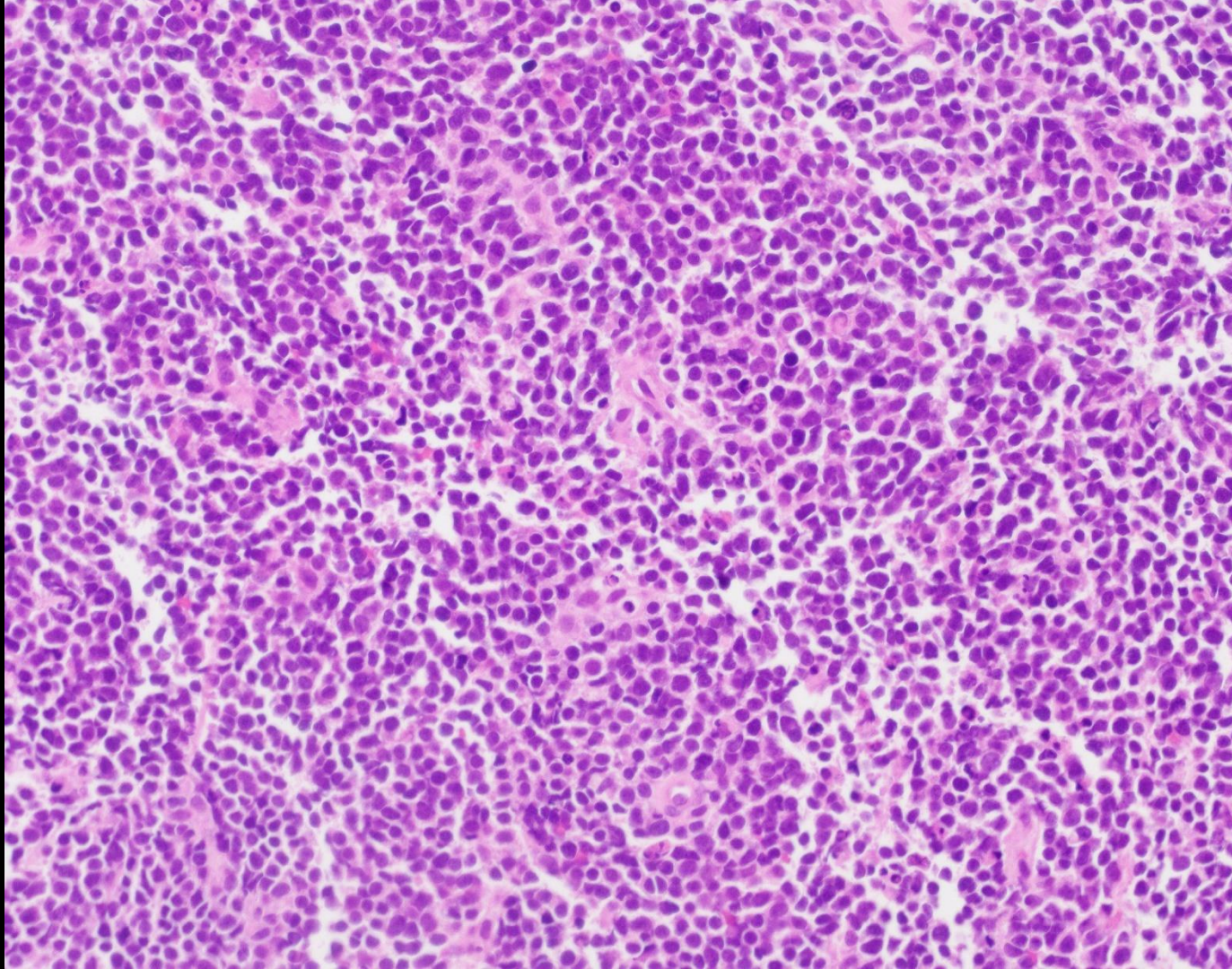
# Burkitt lymphoma with 11q aberration

- Resembles Burkitt lymphoma (morphology; phenotype CD10+, Bcl-2-, Myc+; microRNA and gene expression)
- Negative MYC gene rearrangement, and 1q gain
- 11q proximal gains and telomeric losses in specific regions (array), often with a more complex karyotype
- Some pleomorphism, nodular/follicular growth
- CD16/56+, without CD38high+

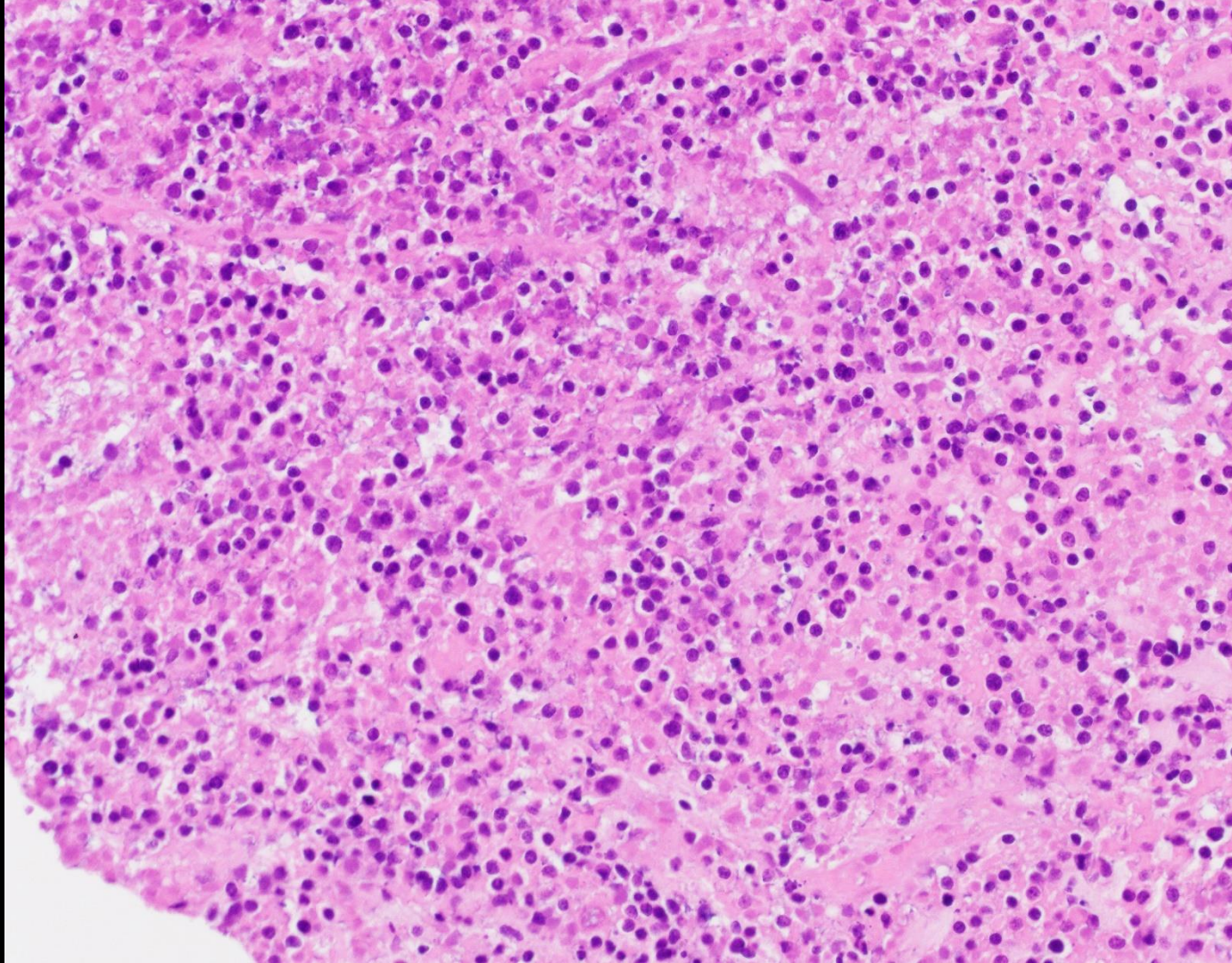
Case 3



# Case 3

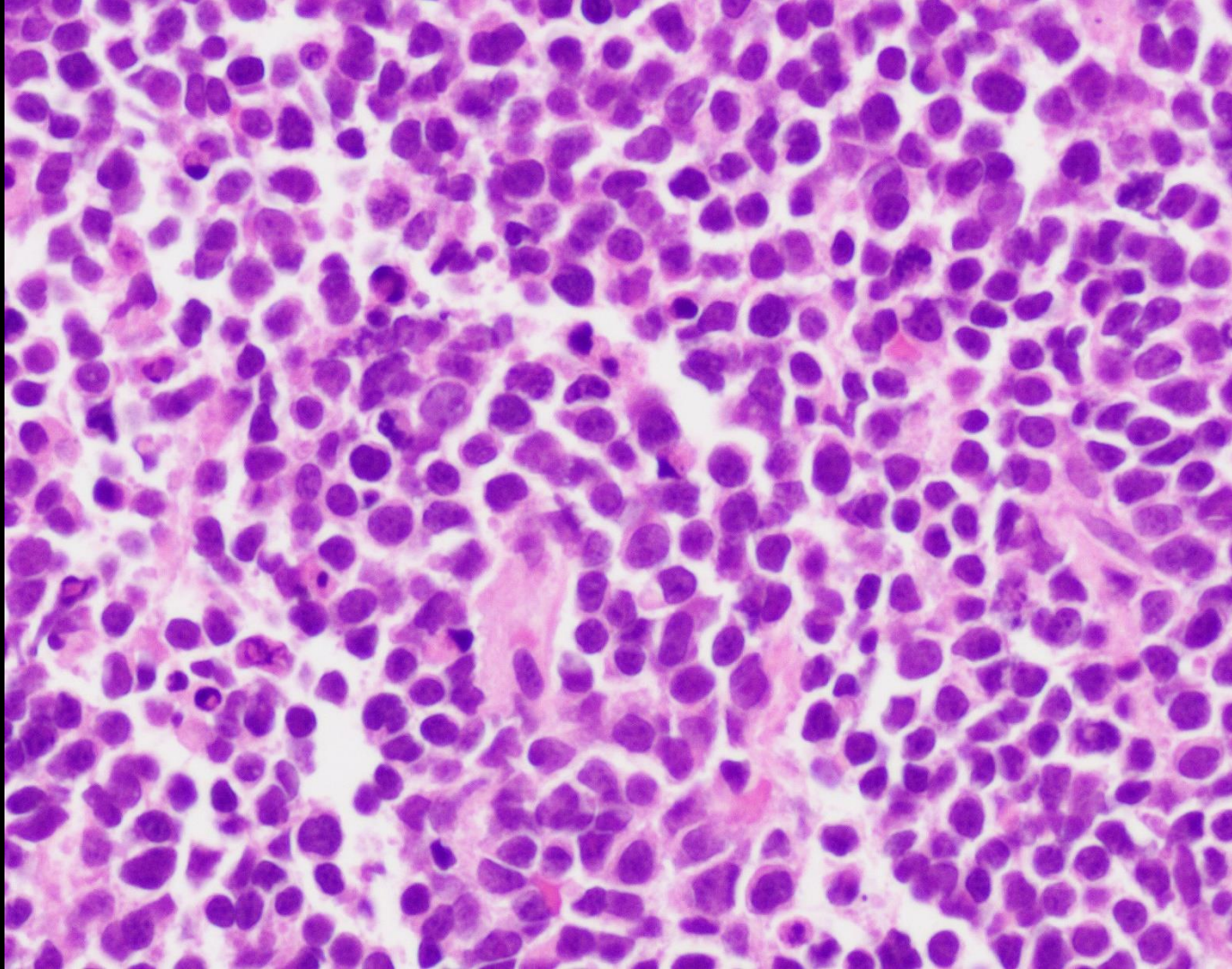


Case 3

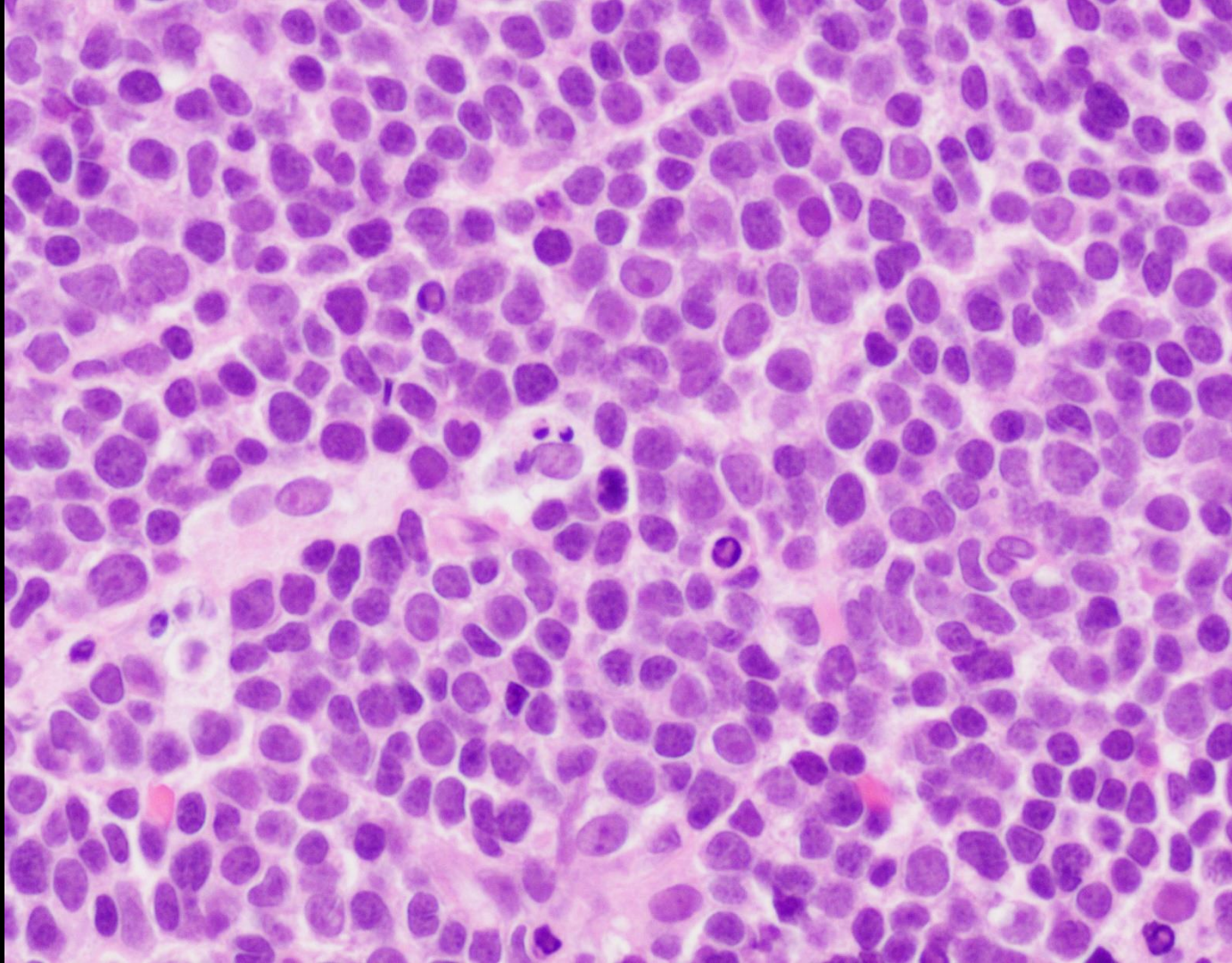




Case 3



# Case 3



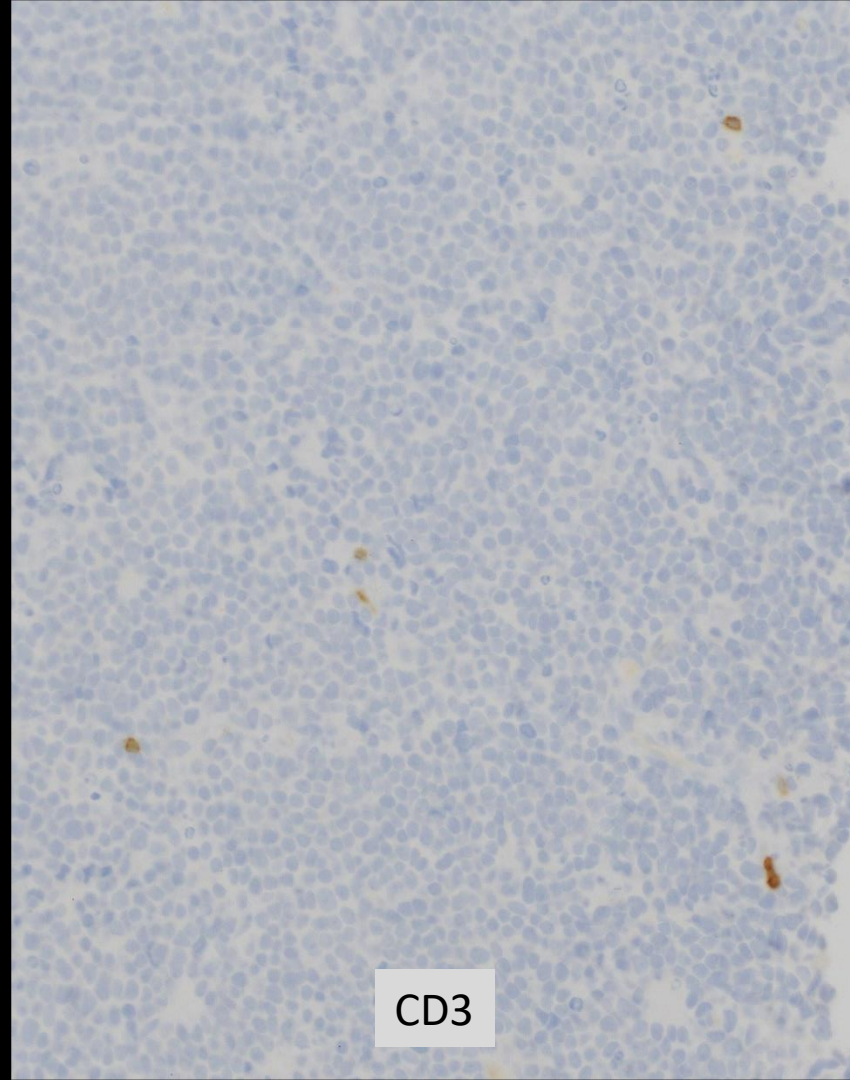
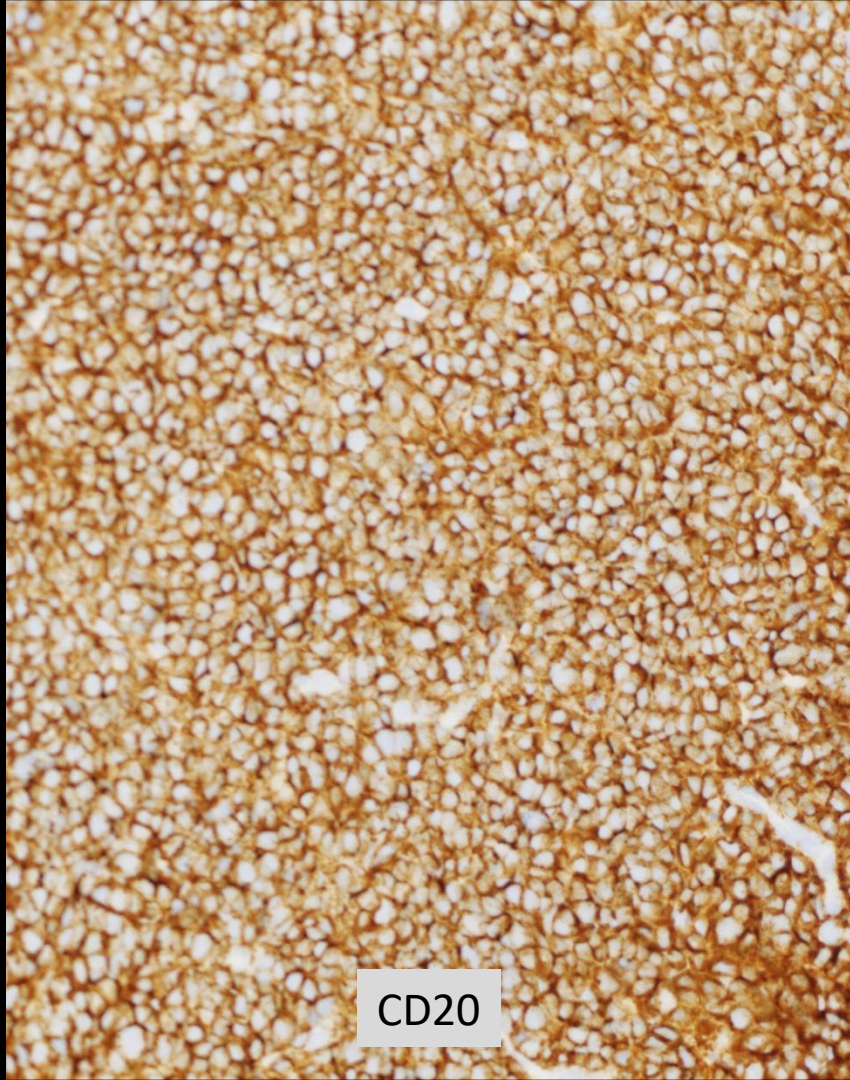If preliminary diagnosis is required before FISH studies are completed, consider using one of the following two options based on the morphologic features:

Appearance  
compatible with  
DLBCL

Blastoid  
appearance

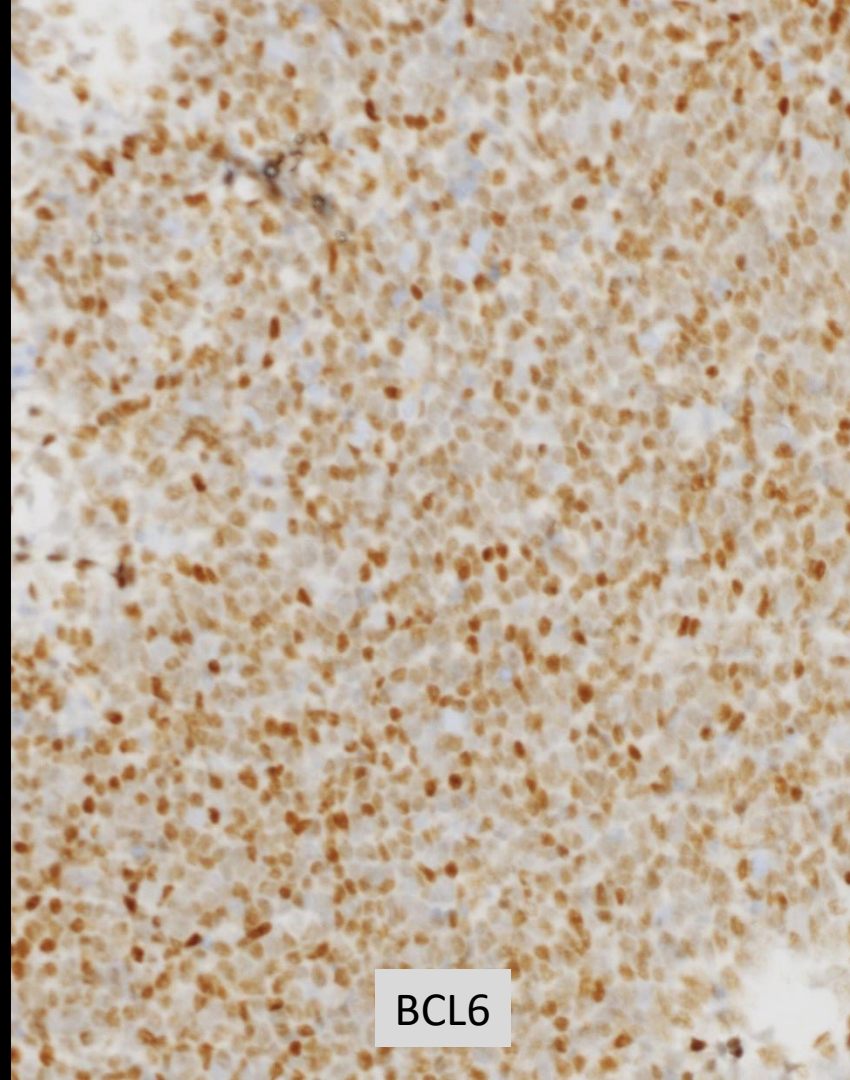
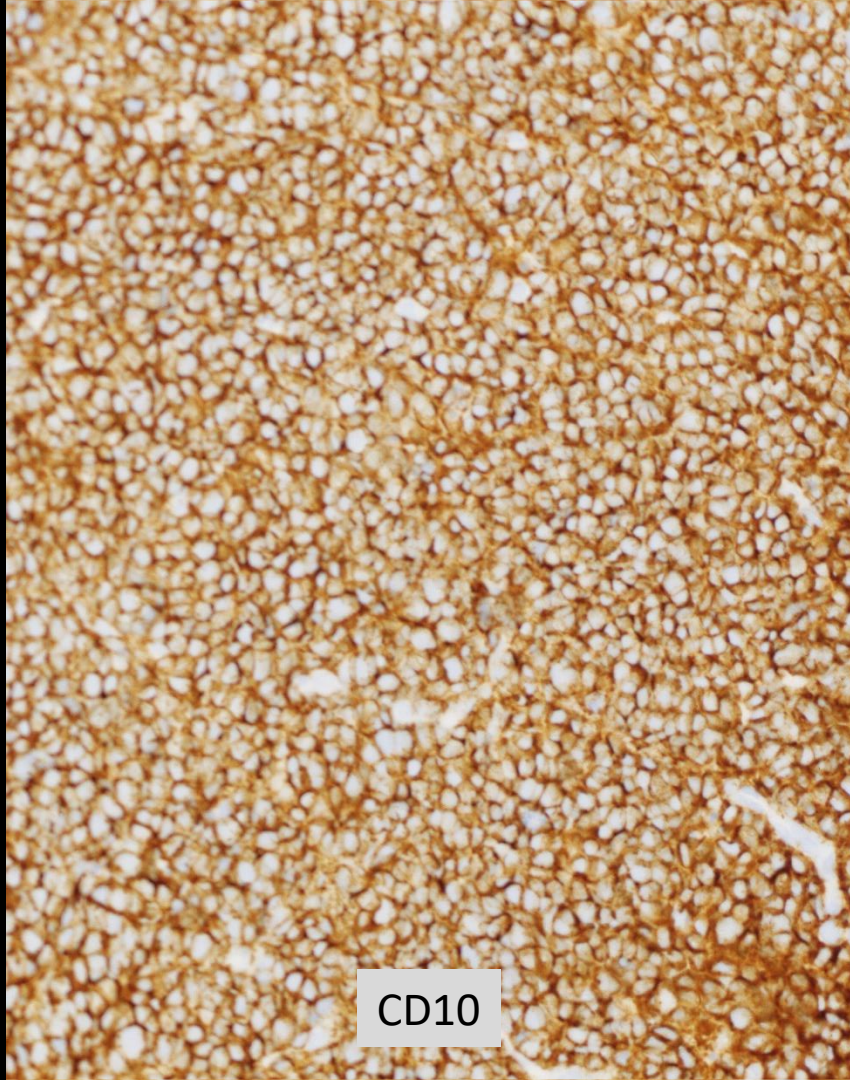“B-cell lymphoma, diffuse large  
or high-grade; pending  
additional studies for further  
classification”

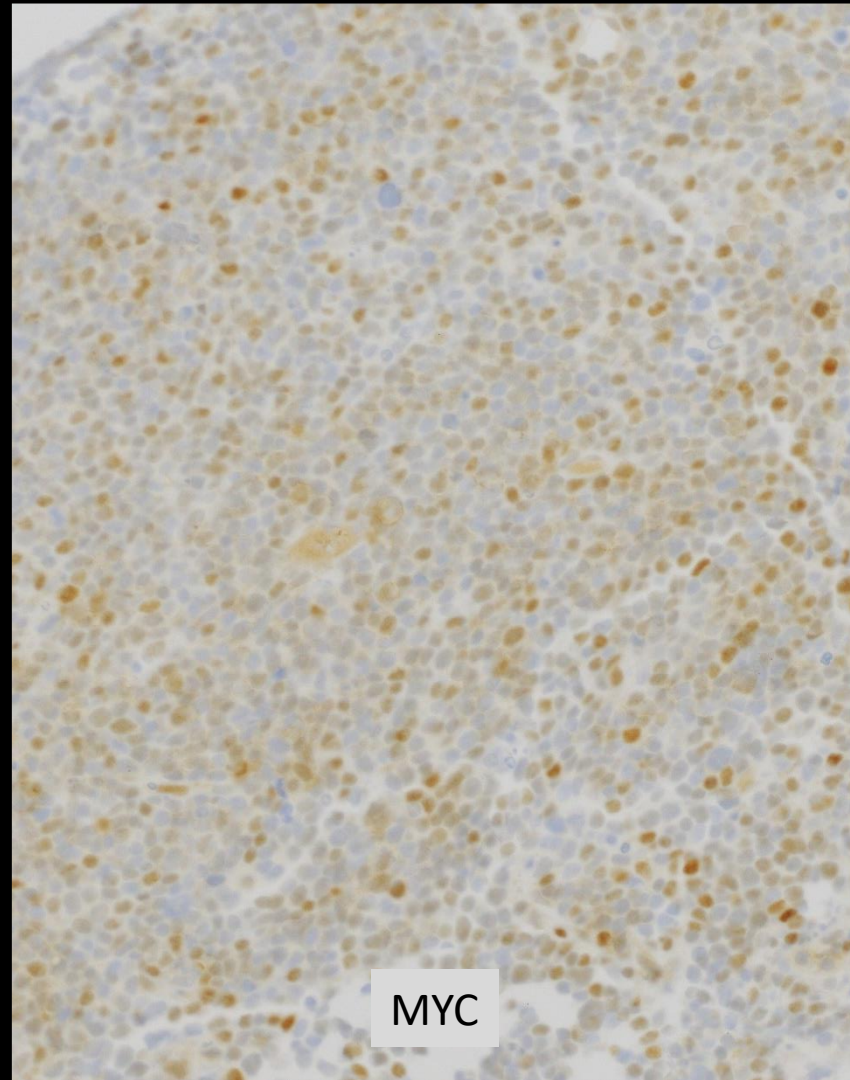
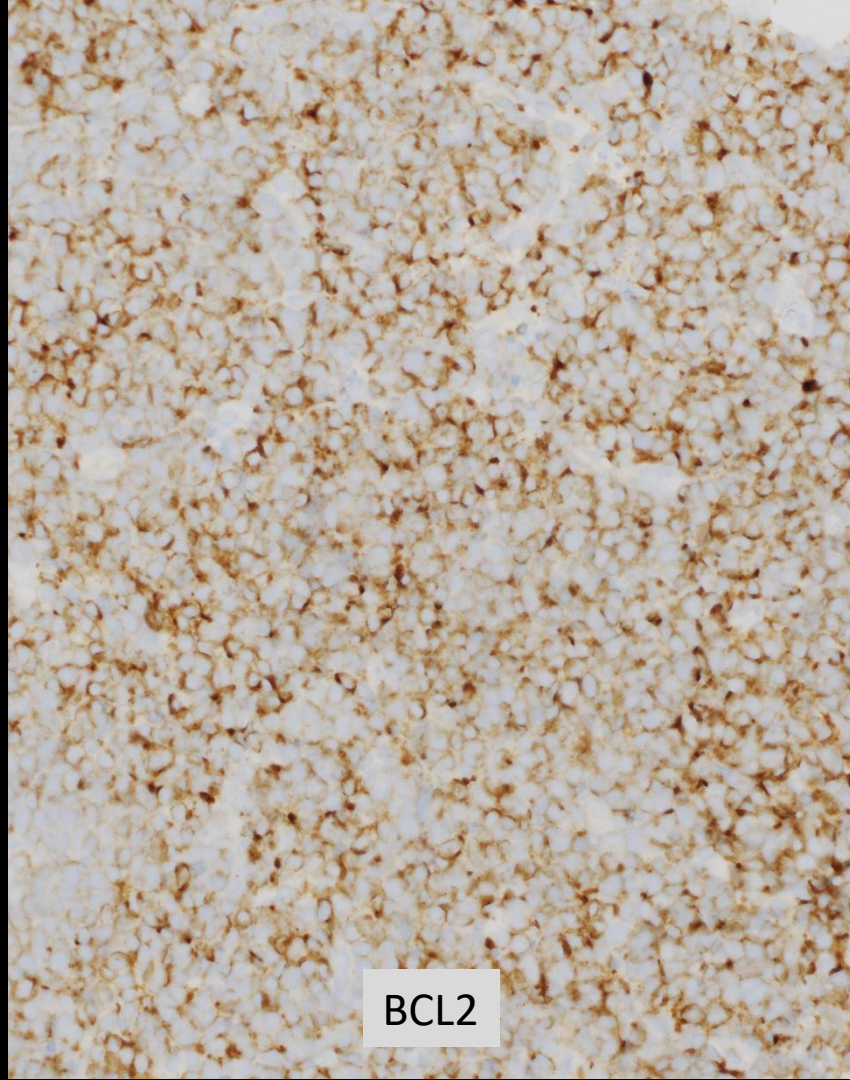
“B-cell lymphoma, high-grade;  
pending additional studies for  
further classification”



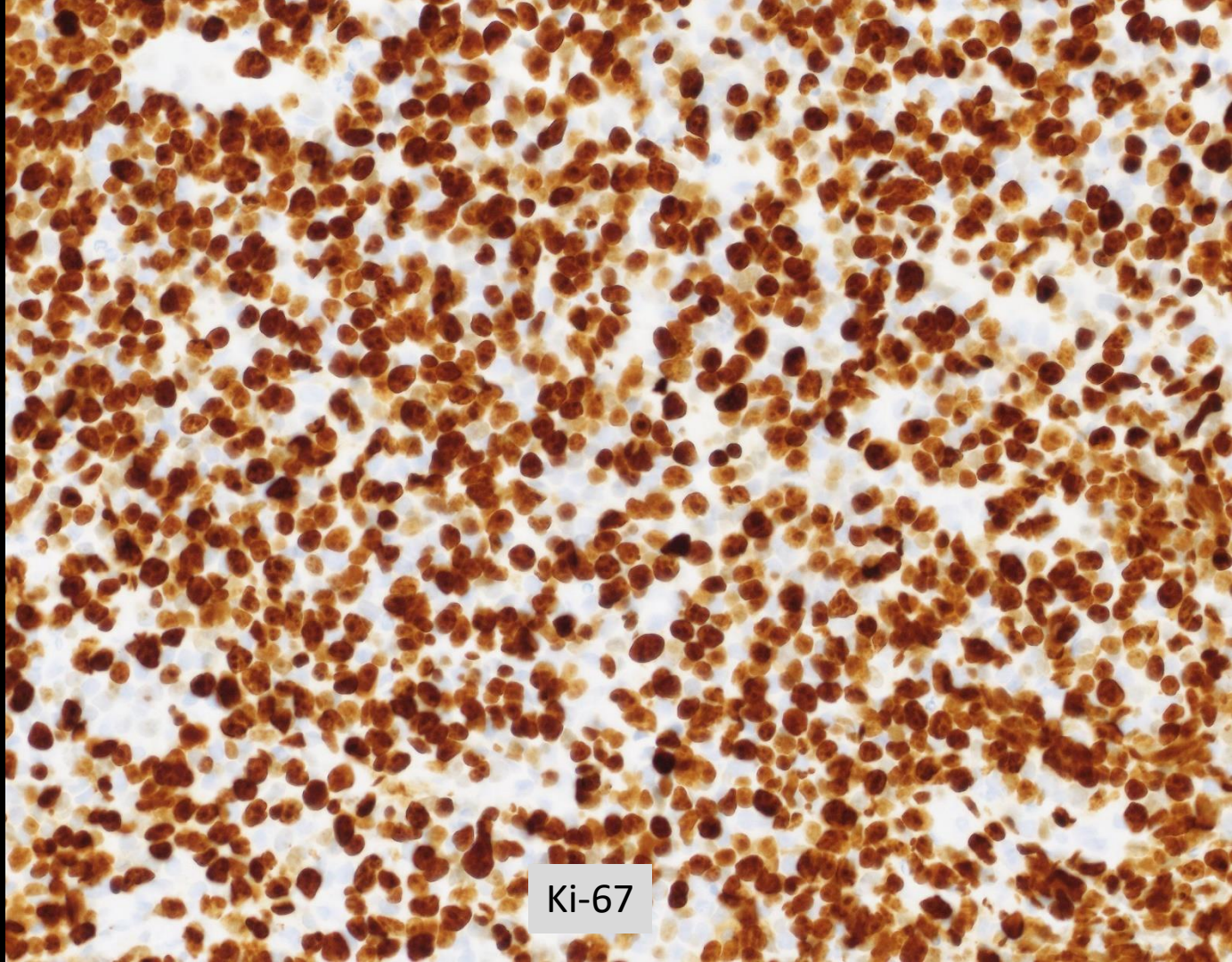
Submit for additional studies, as tissue permits, with the following priority:

1. Fluorescence in situ hybridization (FISH) studies for rearrangement of MYC and BCL2 and/or BCL6 genes (recommended using both MYC break-apart and MYC/IGH fusion probes).
2. Cell of Origin for DLBCL either by IHC using the Hans algorithm (CD10, BCL6, MUM1) or Lymph2Cx gene expression profiling.
3. BCL2 and MYC protein expression by IHC for DLBCL double expresser status.
4. Consider EBER in situ hybridization for Epstein-Barr virus (EBV), if clinically indicated.





# Case 3



Ki-67



## Case 3:

- Fluorescence in situ hybridization studies (reported results from outside institution):
  - Positive for rearrangement of MYC (78%), BCL2 (68.0%) and BCL6 (81%) genes (triple hit)

“B-cell lymphoma, high-grade;  
pending additional studies for  
further classification”

Presence  
*MYC* and *BCL2* and/or  
*BCL6* rearrangements  
by FISH, and other  
features

Presence  
*MYC* gene  
rearrangem  
ent only,  
and other  
features

Absence  
*MYC* and *BCL2*  
and/or *BCL6*  
rearrangements  
by FISH, and  
other features

HGBCL with *MYC* and *BCL2*  
and/or *BCL6*  
rearrangements

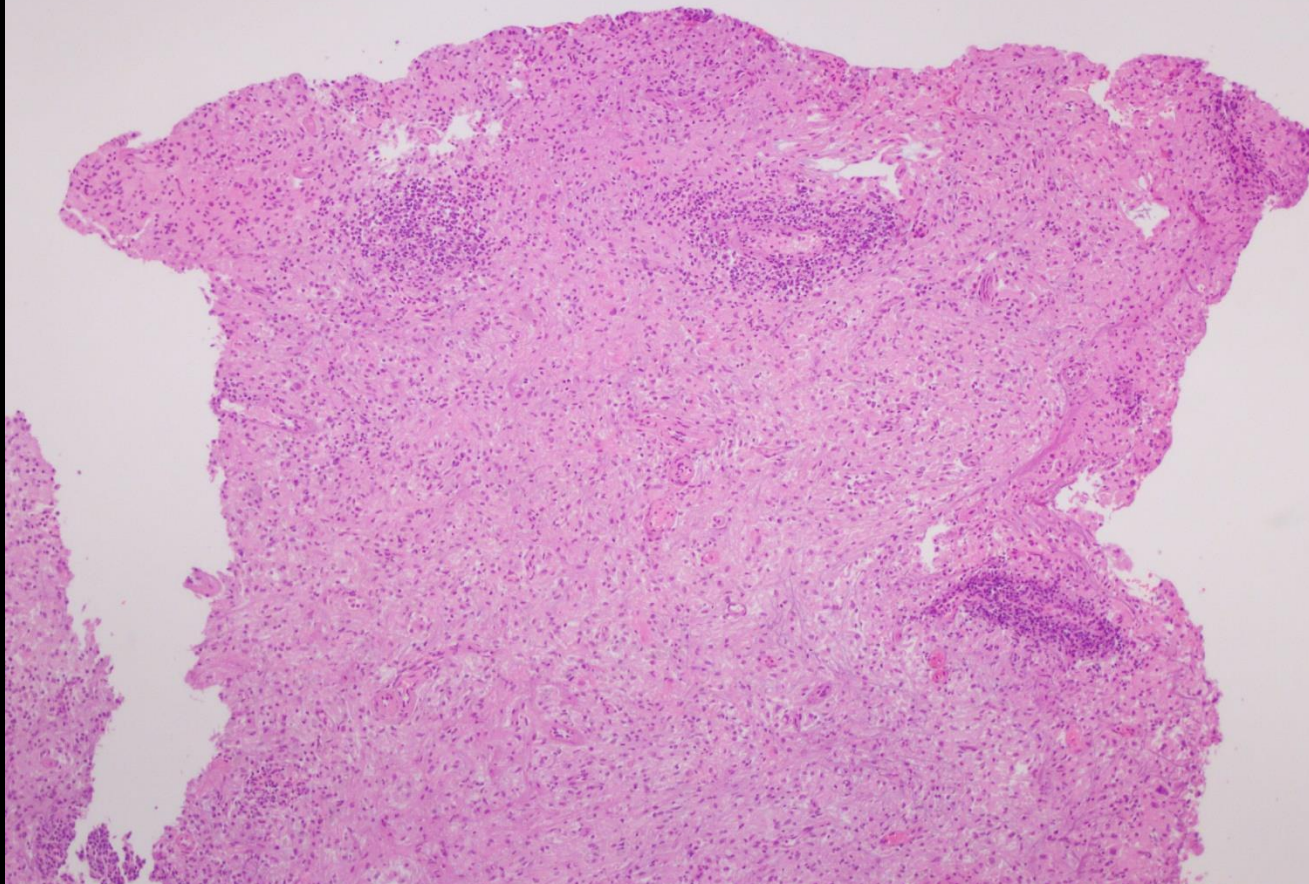
Burkitt  
lymphoma

HGBCL, NOS

# HGBCL with MYC and BCL2 &/or BCL6

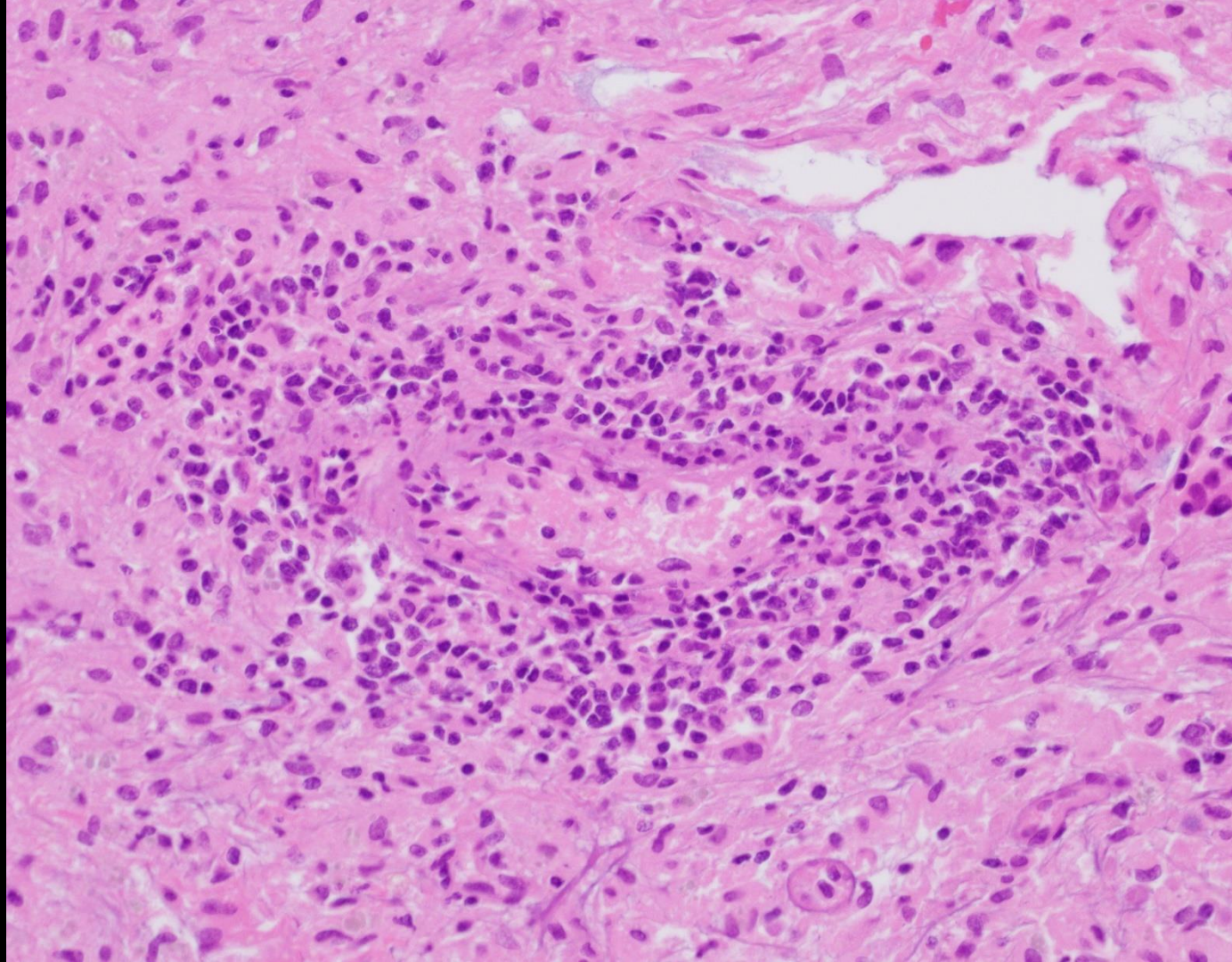
- Morphology resembles DLBCL (50%) or HGBCL
- Most GCB phenotype, CD38br+, Bcl-2+, Myc+, but not sensitivity or specificity to use as a screen
- Most high Ki-67, but not sensitivity as a screen
- Present with advanced stage disease, extranodal involvement, CNS and BM
- Poor response to therapy / prognosis

## Case 4

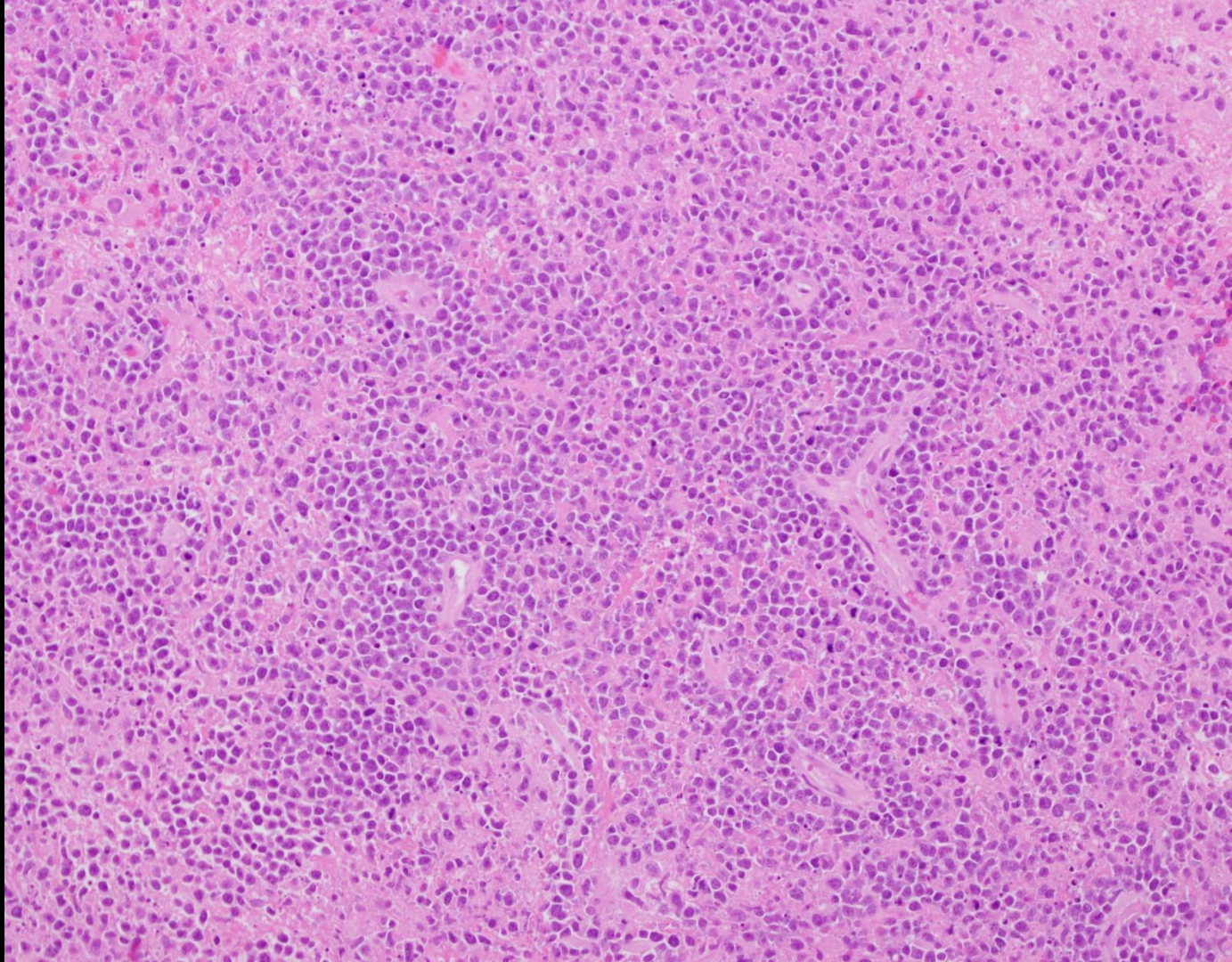


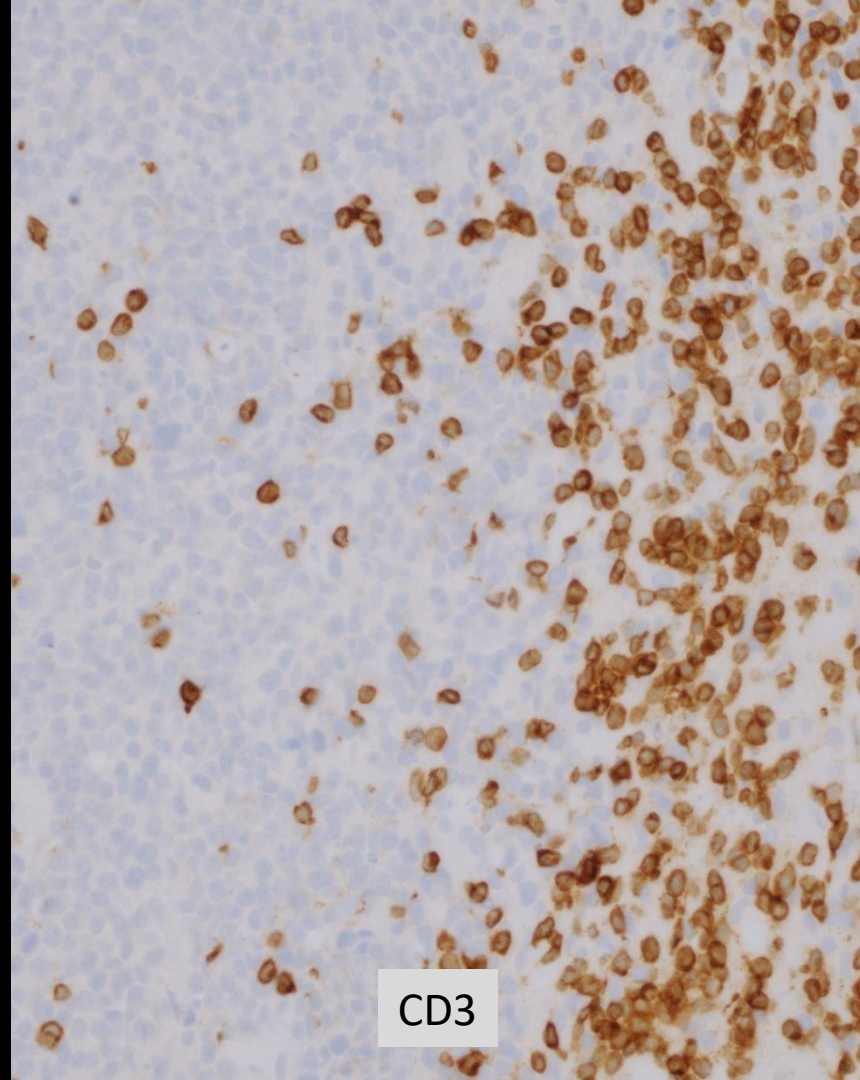
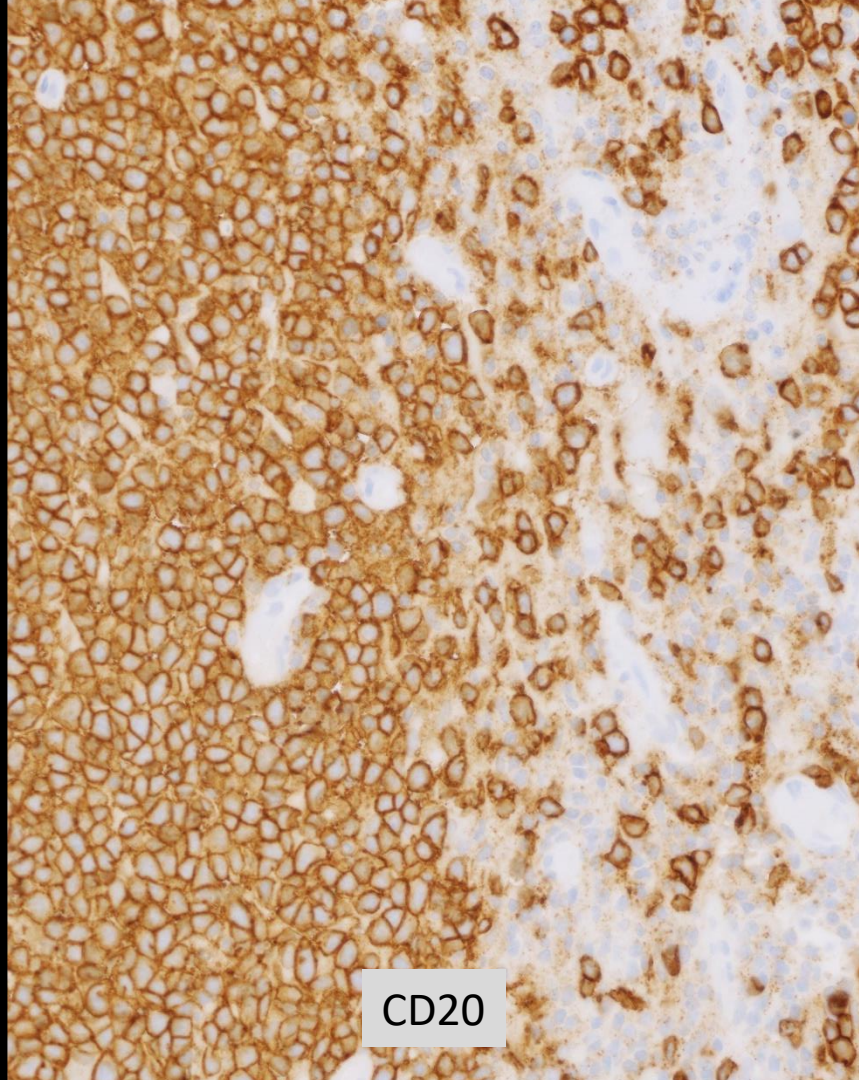
74 year old woman with a left frontal brain mass

Case 4

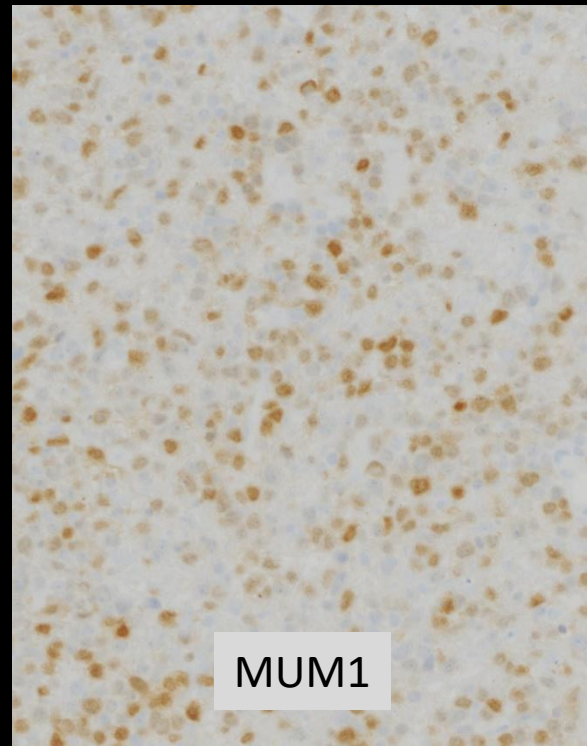
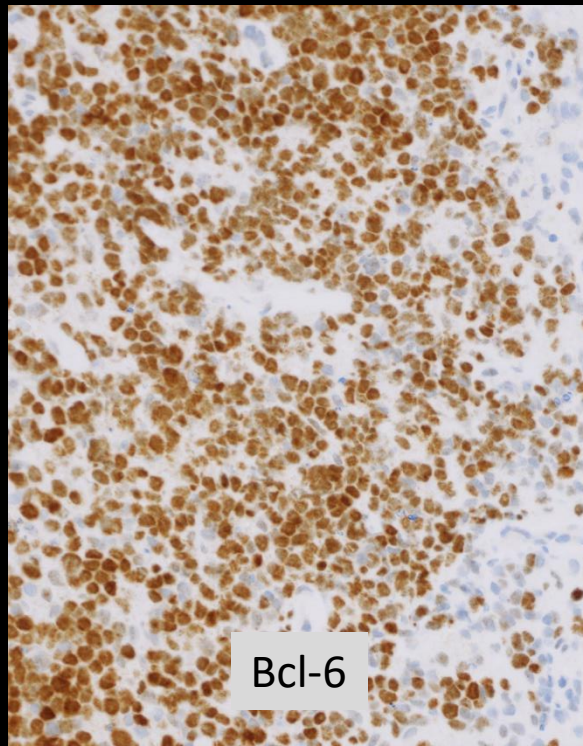
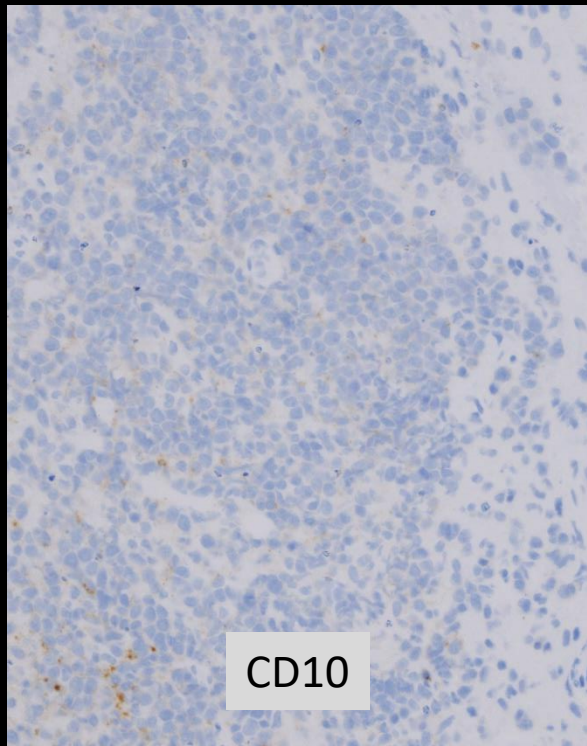


# Case 4





# Case 4





## Case 4:

- Positive MYD88 L265P alteration
- Prior vitreous fluid specimen demonstrating large B-cell lymphoma, also positive for MYD88 L265P alteration

# Primary DLBCL of the CNS

- Brain, spinal cord, leptomeninges (not dura), eye (not 2° or immunodeficiency associated)
- Diffuse with peripheral perivascular islands, and necrosis
- Centroblastic, immunoblastic, or blastoid (similar to Burkitt)
- CD10+ <10%, Bcl-6+ 60-80%, MUM1+ 90% (late GC / ABC)
- ~80% double expresser (Bcl-2+, Myc+), Ki67 > 70%
- Negative EBV, HHV8, SV40, and BK virus
- No rearrangement of MYC or BCL2 genes
- MYD88 L265P > 50%

# Primary mediastinal LBCL

- Localized anterior mediastinum
- Centroblastic or sometimes multilobulated nuclei, moderate to abundant clear cytoplasm
- Fine compartmentalizing fibrosis
- Often slg(-), CD23, CD30, MAL, PD-L2, TRAF and c-REL
- Gene expression profiling, FFPE “PMBCX”
- Benefit from dose-intense chemotherapy regimens

# Lymphoma with plasmablastic features

- Often lack B-cell, and other, antigen expression:
  - CD20(-), Pax-5(-), even CD79a(-), CD45dim+/-
- Variable CD138, CD43, CD57, CD4, CD30, EMA
- Evaluate for EBV, HHV8, ALK-1 (cyclin-D1, CD56)
- Consider distribution of disease e.g. PEL, oral, bone marrow, and history of immunodeficiency...

# Diffuse large B-cell lymphoma (DLBCL): review and refresh

1. Describe features characteristic of DLBCL, NOS, and outline an approach to diagnosis that includes consideration of small biopsy specimens.
2. Discuss the distinction between DLBCL, NOS and other subtypes of large B-cell lymphoma including EBV-positive DLBCL, primary DLBCL of the CNS, primary mediastinal large B-cell lymphoma, and ALK-positive large B-cell lymphoma.
3. Discuss the distinction between DLBCL and high-grade B-cell lymphoma, including Burkitt lymphoma, Burkitt-like lymphoma with 11q aberration, and high-grade B-cell lymphoma with MYC and BCL2 and/or BCL6 rearrangements.